

A Combined Approach of Amniotic Membrane and Oral Mucosa Transplantation for Fornix Reconstruction in Severe Symblepharon

Ahmad Kheirkhah, MD, Reza Ghaffari, MD, Reza Kaghazkanani, MD, Hassan Hashemi, MD, Mahmoud Jabbarvand Behrouz, MD, and Vadrevu K. Raju, MD, FRCS

Purpose: To evaluate the results of a combined approach of cicatrix lysis, intraoperative mitomycin C (MMC) application, oral mucosal transplantation (OMT), and amniotic membrane transplantation (AMT) for surgery of severe symblepharon.

Methods: This prospective study included 32 eyes with severe symblepharon in which after cicatrix lysis the residual conjunctiva was not enough to cover the tarsus (grade III symblepharon) or there was no residual conjunctiva (grade IV symblepharon). After symblepharon lysis and MMC application, OMT was used to cover the tarsus throughout to fornix, and AMT with fibrin glue was performed to cover the exposed sclera. Outcome was defined as complete success (restoration of an anatomically deep fornix), partial success (focal recurrence of scar), or failure (return of symblepharon).

Results: Etiology of symblepharon included chemical burn (n = 16), thermal burn (n = 7), Stevens–Johnson syndrome (n = 5), mucous membrane pemphigoid (n = 2), xeroderma pigmentosum (n = 1), and graft-versus-host disease (n = 1). Motility restriction was present in 87.5% preoperatively. After a mean follow-up of 16.4 ± 7.6 months, the anatomical outcome included complete success in 84.4%, partial success in 9.4%, and failure in 6.2%. In grades III and IV symblephara, the outcomes were complete success in 89.5% and 76.9%, partial success in 10.5% and 7.7%, and failure in none and 15.4%, respectively. No motility restriction was noted in any eye postoperatively. Complications included entropion (n = 2), ocular surface keratinization (n = 1), and pyogenic granuloma (n = 4).

Conclusions: In severe symblepharon, a combined approach of cicatrix lysis, MMC application, OMT, and sutureless AMT was a safe and effective technique for fornix reconstruction.

Key Words: amniotic membrane transplantation, mitomycin C, oral mucosal transplantation, symblepharon

(*Cornea* 2013;32:155–160)

Symblepharon may be caused by various ocular surface diseases, most notably chemical and thermal burns and autoimmune diseases such as mucous membrane pemphigoid and Stevens–Johnson syndrome. It may also be a complication of infectious diseases of the conjunctiva. Although symblepharon may be of no clinical significance in some patients, it may affect the ocular surface health by a number of pathogenic mechanisms, including reduction of tear reservoir, interruption of tear flow and spread, blink-related microtrauma resulting from irregular tarsal surface, cicatricial entropion, and limitation of ocular motility.^{1,2}

To address symptomatic symblepharon, various surgical techniques have been developed over time. Symblepharon lysis invariably creates a defect in the conjunctiva, which, if left uncovered, may lead to re-adhesion of the exposed surfaces. To cover the tarsal and/or bulbar conjunctival defects, a number of tissues have previously been used, including conjunctival graft, amniotic membrane, oral mucosa, nasal mucosa, and split-thickness skin graft.^{3–10} Furthermore, adjunctive measures may also be used to further prevent the reformation of adhesion; these may include intraoperative mitomycin C (MMC) application,¹¹ symblepharon ring,¹² or postoperative application of beta irradiation.¹³ However, it remains mostly unknown which surgical technique has the optimal results for eyes with severe symblepharon.

In our previous retrospective review of various surgical procedures in eyes with different grades of symblepharon severity,¹⁴ it was concluded that satisfactory outcomes may be achieved by fornix reconstruction using a combined approach of cicatrix lysis, intraoperative MMC application, oral mucosal transplantation (OMT), and amniotic membrane transplantation (AMT). Herein, we report our prospective study of using this combined approach in management of eyes with severe symblepharon.

MATERIALS AND METHODS

This prospective noncomparative study included 32 eyes of 32 patients who had severe symblepharon in which after symblepharon lysis, the residual conjunctiva was not enough to

Received for publication September 2, 2011; revision received November 28, 2011; accepted December 15, 2011.

From the Eye Research Center, Farabi Eye Hospital, Tehran University of Medical Sciences, Tehran, Iran.

The authors state that they have no proprietary interest in the products named in this article.

Supplemental digital content is available for this article. Direct URL citations appear in the printed text and are provided in the HTML and PDF versions of this article on the journal's Web site (www.corneajrnl.com).

Reprints: Ahmad Kheirkhah, Eye Research Center, Farabi Eye Hospital, Tehran University of Medical Sciences, Qazvin Square, South Kargar St, Tehran 1336616351, Iran (e-mail: akheirkh@yahoo.com).

Copyright © 2012 by Lippincott Williams & Wilkins

cover the entire tarsus (grade III symblepharon) or there was no residual conjunctiva because of adhesion of the lid margin to the cornea and/or sclera (grade IV symblepharon).¹⁴

Before surgery, all forms of ocular surface inflammation were controlled as much as possible. In patients with chemical/thermal burns, the surgery was performed at least 6 months after the initial injury to allow possible resolution of the inflammation. Furthermore, patients with mucous membrane pemphigoid were treated with systemic immunosuppression (including oral cyclophosphamide) to achieve a noninflamed eye for at least 6 months preoperatively. Patients with severe dry eye despite previous punctal occlusion were excluded from the study. Before enrollment, advantages and disadvantages of the surgery were thoroughly explained to the patients and all consented to participate in the study. The protocol of the study was approved by Institutional Review Board of Farabi Eye Hospital, Tehran, Iran.

Surgical Technique

All surgeries were performed by one surgeon (AK). After using lid margin and limbal traction sutures, symblepharon was released by dissecting the conjunctiva at the limbus and/or cornea. All adhesions of the residual conjunctiva and/or lid margin to the sclera were meticulously dissected to expose the bare sclera. Then, subconjunctival fibrovascular tissue was extensively removed without excision of any conjunctival tissue. All scarred tissues around the insertion of rectus muscles, if present, were excised to achieve a freely mobile globe. At this stage, there was no residual tarsal conjunctiva (grade IV symblepharon) or the residual tarsal conjunctiva was not sufficient to cover the whole width of the tarsus (grade III symblepharon). After minimal cauterization of the bleeding vessels, multiple pieces of the surgical sponge soaked in 0.04% MMC were applied into the fornix for 5 minutes; then, the eye was washed with 100 mL of balanced salt solution.

An oral mucosal graft with a 30% larger size than that of the tarsal conjunctival defect was harvested from the lower lip using manual dissection. The submucosal tissue was shaved off to obtain a thin graft. The anterior edge of the oral mucosal graft was sutured to the residual conjunctival edge (in grade III symblepharon) or the lid margin (in grade IV symblepharon) using 8-0 Vicryl suture with a continuous lock technique. Posterior border of the oral mucosal graft was secured deep into the fornix using 1 transcutaneous double-armed 5-0 polypropylene suture (Ethicon Inc, Somerville, NJ) in each quadrant (anchoring suture). Then, a single layer of cryopreserved amniotic membrane, stromal side down, was used to cover the exposed sclera using fibrin glue (Tisseel; Baxter Inc, Vienna, Austria). A muscle hook was used to push the amniotic membrane deep into the fornix to create an anatomically deep fornix (see **Video, Supplemental Digital Content 1**, <http://links.lww.com/ICO/A58>). In eyes that initially had significant scar tissue around the insertion of rectus muscle, a single layer of amniotic membrane was wrapped around the muscle insertion with the stromal side facing the muscle.

After surgery, the anchoring sutures were removed after 2 weeks. All patients received topical antibiotics for 3 weeks

and topical steroids for 3 months. Postoperatively, patients were seen at 1 day; 1 week; 2 weeks; and 1, 3, 6, 9, and 12 months after surgery and then as needed. In eyes with severe conjunctival inflammation around the surgical site at 1 month after surgery, 8 mg of triamcinolone acetonide was injected subconjunctivally. In eyes that required an additional surgical procedure for visual rehabilitation, such as limbal stem cell transplantation, it was performed at least 3 to 4 months after the fornix reconstruction surgery.

For surgical outcome, complete success was defined as restoration of an anatomically deep fornix without scar or motility restriction, partial success as a focal recurrence of scar tissue, and failure as the return of symblepharon in the area of surgery.¹⁴

RESULTS

This study included 32 eyes of 32 patients (22 men and 10 women) with a mean age of 47.3 ± 11.9 years (range, 3–85 years). Symblepharon was graded as III in 19 eyes (59.4%) and as IV in the other 13 eyes (40.6%). Etiology of symblepharon included chemical burn ($n = 16$), thermal burn ($n = 7$), Stevens–Johnson syndrome ($n = 5$), mucous membrane pemphigoid ($n = 2$), xeroderma pigmentosum ($n = 1$), and graft-versus-host disease ($n = 1$). Eight eyes (25%) had undergone previous surgeries for fornix reconstruction without using OMT, with a mean of 2.5 ± 2.3 previous operations (range, 1–7). In addition, 28 eyes (87.5%) had motility restriction before surgery.

Surgery was uneventful in all cases. After surgery, secured attachments of the oral mucosa and amniotic membrane grafts to the underlying tissues were achieved in all patients. At 1 month after surgery, 5 eyes (15.6%) developed severe conjunctival inflammation around the surgical site. Subconjunctival injection of triamcinolone acetonide resulted in resolution of the inflammation in all these cases.

The patients were followed up for a mean duration of 16.4 ± 7.6 months (range, 6–22 months) after surgery. Totally, the anatomical outcome included complete success in 27 eyes (84.4%), partial success in 3 eyes (9.4%), and failure in 2 eyes (6.2%). In eyes with grade III symblepharon ($n = 19$), complete success and partial success were achieved in 17 eyes (89.5%) and 2 eyes (10.5%), respectively, and none developed failure (Fig. 1). In eyes with grade IV symblepharon ($n = 13$), these outcomes were observed in 10 eyes (76.9%), 1 eye (7.7%), and 2 eyes (15.4%), respectively (Fig. 2). Table 1 shows the surgical outcome according to the type and the etiology of symblepharon. In all eyes with preoperative motility restriction, free movement of the eye was noted during the entire follow-up after surgery.

The cases with failure included 1 eye with grade IV symblepharon owing to xeroderma pigmentosum, which developed recurrence of symblepharon (grade I) at the margin of the surgical site 3 months postoperatively (Figs. 2G, H), and 1 eye with grade IV symblepharon due to severe thermal burn in a 3-year-old boy who developed recurrent symblepharon (grade II) 2 months after the surgery. The latter case underwent repeat surgery with the same technique resulting in partial success during the 9-month follow-up. The cases with

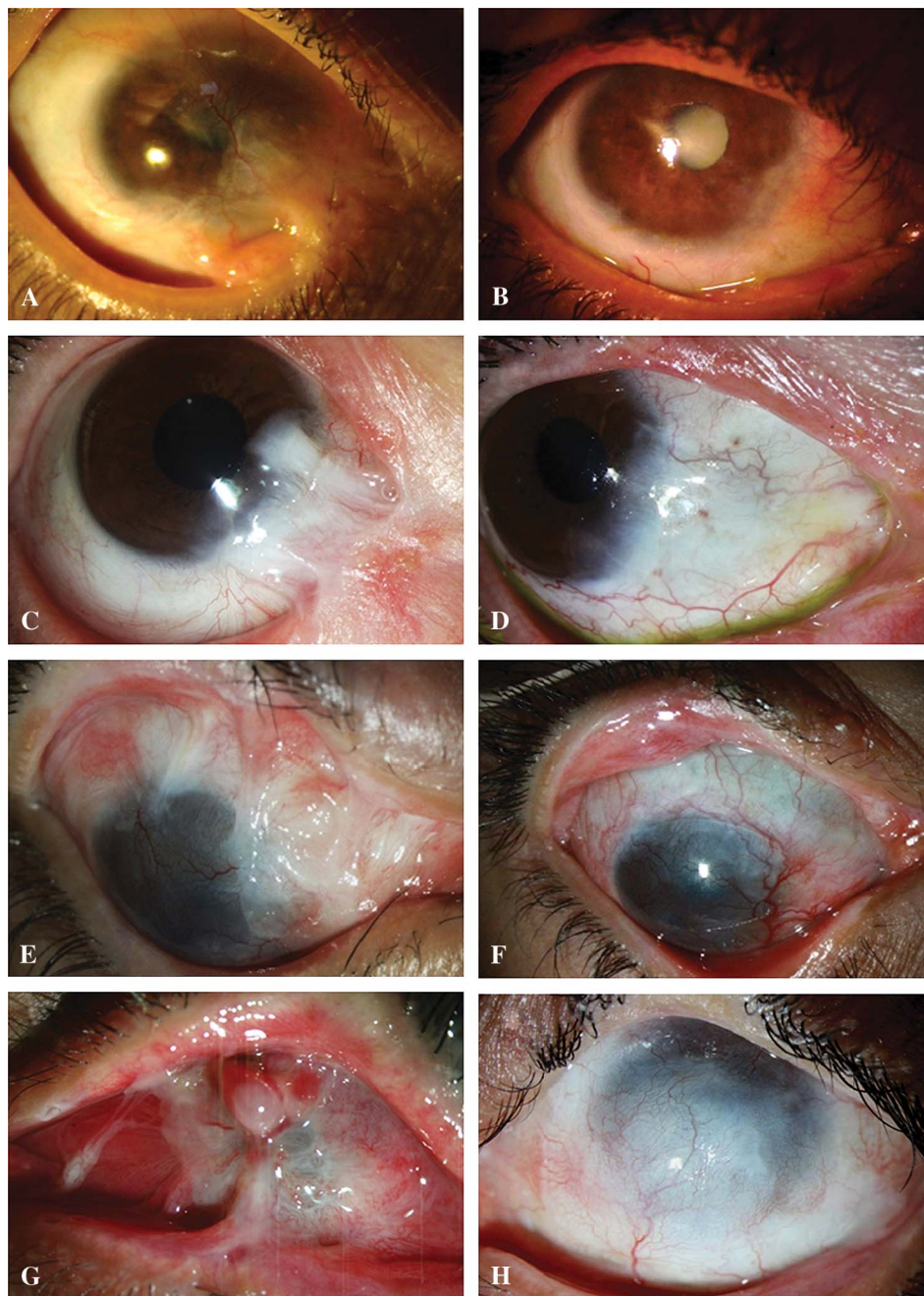


FIGURE 1. Fornix reconstruction using cicatrix lysis, intraoperative MMC application, OMT, and sutureless AMT in eyes with grade III symblepharon; Left column, eyes before surgery and right column, after surgery. A, An eye with severe symblepharon because of chemical burn in the inferonasal fornix with a history of 1 failed reconstructive surgery. B, After surgery with the combined approach, a deep fornix with complete success was achieved during a 14-month follow-up. Notice improvement in the corneal surface and clarity. C, Another eye with severe symblepharon due to chemical burn involving the inferonasal fornix and canthal area underwent surgery. D, During a 12-month follow-up, a deep fornix with complete success was noted. E, A 10-year-old girl with extensive severe symblepharon in the superior and superonasal fornices who had 3 failed previous reconstructive surgeries. F, Complete success was achieved during 19 months of follow-up. G, An eye with extensive symblepharon in superior and inferior fornices due to chemical burn. H, The surgery resulted in a noninflamed surface and partial success with focal scar deep in the fornices during a 20-month postoperative follow-up.

partial success included 1 eye with extensive grade III symblepharon because of chemical burn (Figs. 1G, H), 1 eye with grade IV symblepharon caused by chemical burn and a history of 7 failed reconstructive surgeries (Figs. 2E, F), and 1 eye with grade III symblepharon due to mucous membrane pemphigoid and a history of 2 failed procedures.

After surgery, 2 eyes developed entropion in the operated area; one of these required surgical correction. In addition, 1 eye with graft-versus-host disease and grade IV symblepharon developed keratinization of the ocular surface after surgery even though the dry eye was not severe preoperatively. Pyogenic granuloma developed in 4 cases

(12.5%), and it was resolved by triamcinolone injection (3 eyes) or surgical excision (1 eye). One patient developed increased intraocular pressure after subconjunctival triamcinolone injection that was controlled medically. No complication related to MMC was seen in any eye or was there any significant complication at the donor site of oral mucosal graft.

DISCUSSION

This prospective study showed that a combined approach of cicatrix lysis followed by intraoperative MMC application, OMT, and sutureless AMT was a safe and effective technique

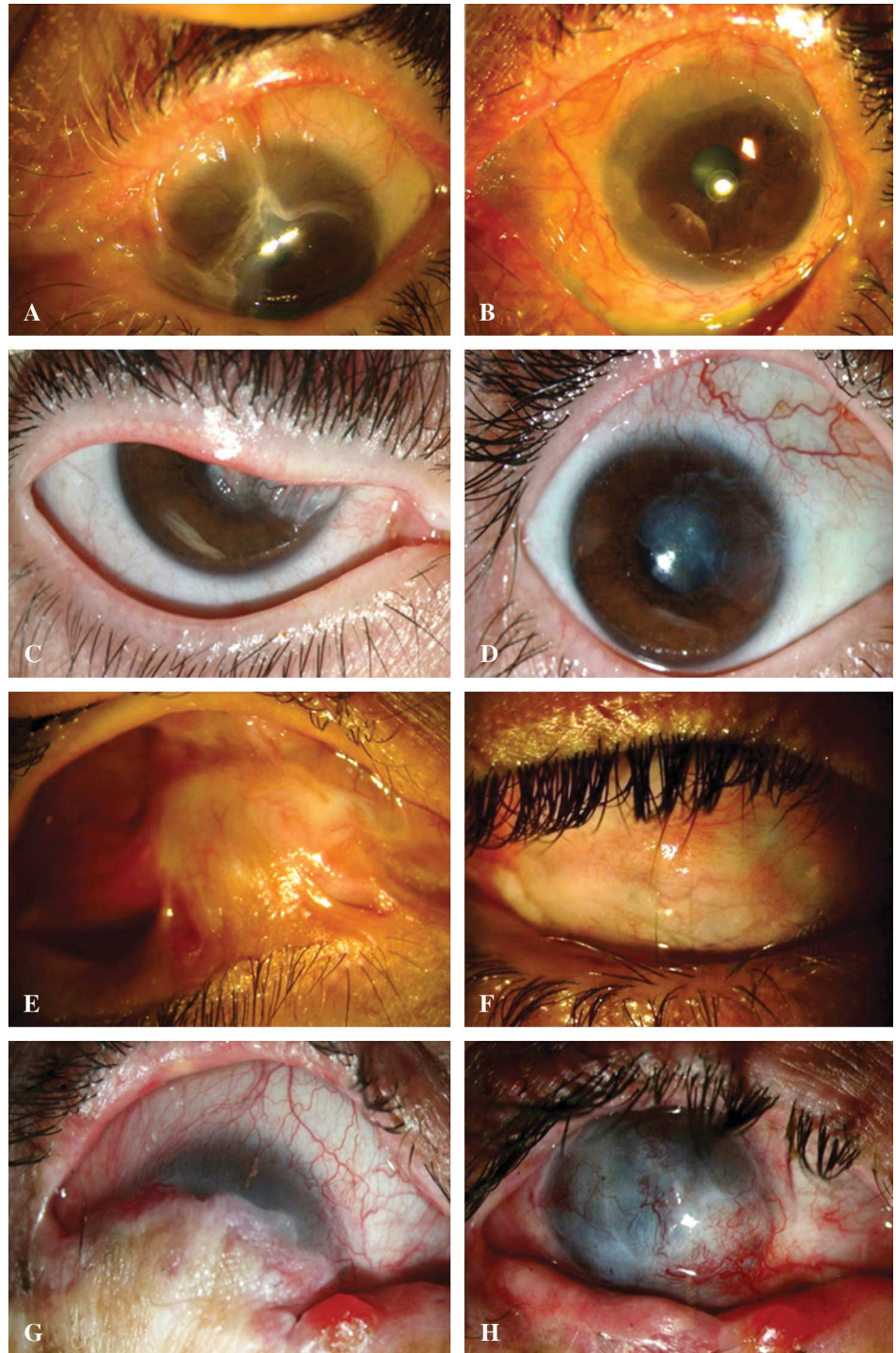


FIGURE 2. Fornix reconstruction using cicatrix lysis, intraoperative MMC application, OMT, and sutureless AMT in eyes with grade IV symblepharon. Left column, eyes before surgery and right column, after surgery. A, An eye with severe symblepharon because of mucous membrane pemphigoid in the entire nasal half of the eye received systemic immunosuppression to suppress inflammatory activity of the disease. B, After surgery with the combined approach, a deep fornix with complete success was achieved during a 16-month follow-up. C, An eye with severe symblepharon due to chemical burn involving superonasal fornix underwent surgery with the combined approach. D, During 8 months of follow-up, a deep fornix with complete success was noted. E, Extensive severe symblepharon in an eye with chemical burn and a history of 7 failed reconstructive surgeries. F, Partial success was achieved with surgery during 15 months of follow-up. G, An eye with severe symblepharon in the entire inferior fornix due to xeroderma pigmentosum underwent surgery. Although the ocular surface improved significantly during a 6-month follow-up (H), the case was considered as failure because of the presence of a grade I symblepharon at the margin of surgical site, which developed 3 months after surgery.

to achieve an anatomically deep fornix during 16.4 ± 7.6 months of postoperative follow-up in 32 eyes with severe symblepharon due to a variety of cicatricial diseases.

In this study, eyes with severe symblepharon (grades III and IV) were included. Symblepharon dissection in these eyes invariably resulted in large conjunctival defects over sclera, fornix, and tarsus. To cover the conjunctival defect, a number of tissues have been used before.³⁻⁹ Although a conjunctival

autograft may be used to cover a small defect, in most of these patients the defect was large and there was no sufficient residual conjunctiva. Furthermore, although autologous nasal mucosa has been used successfully for fornix reconstruction,^{7,8} the technique for harvesting nasal mucosa is complex and challenging.¹⁵

Although AMT alone has been successfully used to reconstruct the fornix in eyes with lower grades of symblepharon

TABLE 1. Anatomical Outcomes of Fornix Reconstruction Using Cicatrix Lysis, Intraoperative MMC Application, OMT, and Sutureless AMT According to the Type and the Etiology of Symblepharon

	Number of Eyes	Anatomical Outcome		
		Complete Success, n (%)	Partial Success, n (%)	Failure, n (%)
Type of symblepharon				
Primary (previously unoperated)	24	21 (87.5)	1 (4.2)	2 (8.3)
Recurrent (previously operated)	8	6 (75)	2 (25)	—
Etiology of symblepharon				
Chemical burn	16	14 (87.5)	2 (12.5)	—
Thermal burn	7	6 (85.7)	—	1 (14.3)
Stevens–Johnson syndrome	5	5 (100)	—	—
Mucous membrane pemphigoid	2	1 (50)	1 (50)	—
Xeroderma pigmentosum	1	—	—	1 (100)
Graft-versus-host disease	1	1 (100)	—	—
Total	32	27 (84.4)	3 (9.4)	2 (6.2)

severity,^{9,10,14} its usefulness is limited in eyes with severe symblepharon. In eyes with grades III and IV symblephara, fornix reconstruction using AMT alone without any mucosal graft has been reported to have complete success in 3 of 7 eyes (42.8%), partial success in 2 of 7 eyes (28.6%), and failure in 2 of 7 eyes (28.6%).¹⁴ This was in contrast to rates of 72.1%, 11.6%, and 16.3% for these outcomes, respectively, with the same technique in eyes with grades I and II symblephara.¹⁴ Therefore, in severe symblepharon, additional mucosal grafting is needed to improve the outcome; for this purpose, oral mucosa may be a proper option. An oral mucosal graft has been used for a long time for covering the conjunctival defects during fornix reconstruction in eyes with symblepharon^{4,14,16,17} or anophthalmic contracted sockets,^{18–20} for cicatricial entropion surgery,^{21,22} for ocular resurfacing before osteo-odontokeratoprosthesis,²³ after pterygium surgery,²⁴ or even to cover a leaking conjunctival bleb.²⁵

In our study, the combination of cicatrix lysis, extensive removal of subconjunctival fibrovascular tissue, intraoperative MMC application, anchoring sutures, AMT, and OMT in cases with severe symblepharon resulted in complete success in 27 eyes (84.4%), partial success in 3 eyes (9.4%), and failure in only 2 eyes (6.2%; Figs. 1 and 2). Better outcome in this study compared with the same technique in the previous study,¹⁴ which showed complete success in 5 of 11 eyes (45.5%) and partial success in 6 of 11 eyes (54.5%), may be because of the use of intraoperative MMC and fibrin glue in all cases, a modification of anchoring sutures, and effective control of inflammation pre- and postoperatively.

Although sutures may be used to secure amniotic membrane, use of fibrin glue avoids suture-related complications and is associated with less postoperative conjunctival inflammation,²⁶ which may improve the outcome of fornix reconstruction surgery. In addition, the surgical outcome in this study was partly contributed by the use of intraoperative MMC, which is known to prevent recurrence of fibrovascular proliferation in pterygium and symblepharon surgeries.^{11,27,28} Instead of 4-0 silk,¹⁴ anchoring sutures made of 5-0 polypropylene were used in the present study to secure the posterior border of the oral mucosal graft deep into the fornix. Because it is known that polypropylene suture is associated with less

inflammation and tissue reaction than silk suture,²⁹ this may explain the lower rate of focal scar, and thus partial success, in the present study. Furthermore, 5 eyes (15.6%) in this study developed postoperative conjunctival inflammation that resolved with subconjunctival injection of triamcinolone. Treatment of such inflammation, which is common after AMT for ocular surface reconstruction,^{14,30,31} may have beneficial effects on the outcome of fornix reconstruction, as has been shown for pterygium surgery.²⁶

Cases with failure in this series included an eye with severe symblepharon due to xeroderma pigmentosum, and an eye with severe thermal burn in a 3-year-old boy. The failure in the former case may have been caused by the progressive shrinkage and loss of tissues, which are known to happen in cases with xeroderma pigmentosum,³² and in the latter case it may be because of the well-known exuberant inflammatory reaction in the young. Although a longer interval between the initial injury and the surgery in children may result in better anatomical outcome because of the reduced ocular surface inflammation, it is associated with higher risk for amblyopia.

Despite its high success rate, use of a large oral mucosal graft may be associated with some complications at the donor site. Although none was seen in this study, complications such as contracture, persistent discomfort, salivary flow changes, and neurosensory deficits have been reported before.^{33,34} To avoid such complications, use of cultivated oral mucosal epithelial sheets, which has been previously reported in patients with limbal stem cell deficiency,³⁵ may be considered.

Complications in this study included entropion in 2 eyes (probably because of scar formation or shrinkage of the graft), ocular surface keratinization in 1 eye, and pyogenic granuloma in 4 eyes. Ocular surface keratinization developed in a patient with graft-versus-host disease who did not have severe dry eye preoperatively. An increased evaporative surface with preexisting borderline tear production might have played a role in the development of such a complication. That is why cases with severe dry eye were excluded from this study, as has been recommended by others.^{16,17}

The main limitations of our study are the lack of a control group and inclusion of symblephara due to various diseases (Table 1), which may require different surgical approaches. However, the majority of our cases were due to chemical or thermal burns. With these limitations in mind, our results showed that a combined approach of cicatrix lysis, intraoperative MMC application, OMT, and sutureless AMT is an effective surgical strategy for the management of severe symblepharon.

REFERENCES

- MacDonald EA, Maurice DM. The kinetics of tear fluid under the lower lid. *Exp Eye Res.* 1991;53:421–425.
- Kaufman HE, Thomas EL. Prevention and treatment of symblepharon. *Am J Ophthalmol.* 1979;88(3 pt 1):419–423.
- Critchett A. A case of complete symblepharon successfully treated by operation. *Br Med J.* 1881;2:934.
- Meighan TS. On an operation for symblepharon by transplantation of mucous membrane from the lip. *Br Med J.* 1889;1:706–707.
- Zelaski SL. Successful repair of total symblepharon with split thickness skin graft. *Bull Kresge Eye Inst.* 1951;3:55–56.
- Hartman DC. Use of free grafts in correction of recurrent pterygia, pseudopterygia and symblepharon. *Calif Med.* 1951;75:279–280.
- Kuckelkorn R, Schrage N, Redbrake C, et al. Autologous transplantation of nasal mucosa after severe chemical and thermal eye burns. *Acta Ophthalmol Scand.* 1996;74:442–448.
- Kim JH, Chun YS, Lee SH, et al. Ocular surface reconstruction with autologous nasal mucosa in cicatricial ocular surface disease. *Am J Ophthalmol.* 2010;149:45–53.
- Tsubota K, Satake Y, Ohyama M, et al. Surgical reconstruction of the ocular surface in advanced ocular cicatricial pemphigoid and Stevens-Johnson syndrome. *Am J Ophthalmol.* 1996;122:38–52.
- Solomon A, Espana EM, Tseng SC. Amniotic membrane transplantation for reconstruction of the conjunctival fornices. *Ophthalmology.* 2003;110:93–100.
- Tseng SC, Di Pascuale MA, Liu DZ, et al. Intraoperative mitomycin C and amniotic membrane transplantation for fornix reconstruction in severe cicatricial ocular surface diseases. *Ophthalmology.* 2005;112:896–903.
- Patel BC, Sapp NA, Collin R. Standardized range of conformers and symblepharon rings. *Ophthalm Plast Reconstr Surg.* 1998;14:144–145.
- Fein W. Repair of total and subtotal symblepharons. *Ophthalmic Surg.* 1979;10:44–47.
- Kheirkhah A, Blanco G, Casas V, et al. Surgical strategies for fornix reconstruction based on symblepharon severity. *Am J Ophthalmol.* 2008;146:266–275.
- Schrader S, Notara M, Beaconsfield M, et al. Tissue engineering for conjunctival reconstruction: established methods and future outlooks. *Curr Eye Res.* 2009;34:913–924.
- Shore JW, Foster CS, Westfall CT, et al. Results of buccal mucosal grafting for patients with medically controlled ocular cicatricial pemphigoid. *Ophthalmology.* 1992;99:383–395.
- Heiligenhaus A, Shore JW, Rubin PA, et al. Long-term results of mucous membrane grafting in ocular cicatricial pemphigoid. Implications for patient selection and surgical considerations. *Ophthalmology.* 1993;100:1283–1288.
- Karesh JW, Putterman AM. Reconstruction of the partially contracted ocular socket or fornix. *Arch Ophthalmol.* 1988;106:552–556.
- Klein M, Menneking H, Bier J. Reconstruction of the contracted ocular socket with free full-thickness mucosa graft. *Int J Oral Maxillofac Surg.* 2000;29:96–98.
- Bowen Jones EJ, Nunes E. The outcome of oral mucosal grafts to the orbit: a three-and-a-half-year study. *Br J Plast Surg.* 2002;55:100–104.
- Halasa A. Mucous membrane transplant for the correction of cicatricial entropion. *Eye Ear Nose Throat Mon.* 1966;45:88–89.
- Hosni FA. Repair of trachomatous cicatricial entropion using mucous membrane graft. *Arch Ophthalmol.* 1974;91:49–51.
- Hille K, Grabner G, Liu C, et al. Standards for modified osteodentokeratoprostheses (OOKP) surgery according to Strampelli and Falcinelli: the Rome-Vienna Protocol. *Cornea.* 2005;24:895–908.
- Forbes J, Collin R, Dart J. Split thickness buccal mucous membrane grafts and beta irradiation in the treatment of recurrent pterygium. *Br J Ophthalmol.* 1998;82:1420–1423.
- Rootman DB, Kumar NL, Rootman DS, et al. Buccal mucous membrane for the reconstruction of complicated leaking trabeculectomy blebs. *J Glaucoma.* 2010;19:270–274.
- Kheirkhah A, Casas V, Sheha H, et al. Role of conjunctival inflammation in surgical outcome after amniotic membrane transplantation with or without fibrin glue for pterygium. *Cornea.* 2008;27:56–63.
- Murakami M, Mori S, Kunitomo N. Studies on the pterygium. V. Follow-up information of mitomycin C treatment [Article in Japanese]. *Nihon Ganka Gakkai Zasshi.* 1967;71:351–358.
- Abraham LM, Selva D, Casson R, et al. Mitomycin: clinical applications in ophthalmic practice. *Drugs.* 2006;66:321–340.
- Tajirian AL, Goldberg DJ. A review of sutures and other skin closure materials. *J Cosmet Laser Ther.* 2010;12:296–302.
- Kheirkhah A, Casas V, Blanco G, et al. Amniotic membrane transplantation with fibrin glue for conjunctivochalasis. *Am J Ophthalmol.* 2007;144:311–313.
- Kheirkhah A, Nazari R, Nikdel M, et al. Postoperative conjunctival inflammation after pterygium surgery with amniotic membrane transplantation versus conjunctival autograft. *Am J Ophthalmol.* 2011;152:733–738.
- Ramkumar HL, Brooks BP, Cao X, et al. Ophthalmic manifestations and histopathology of xeroderma pigmentosum: two clinicopathological cases and a review of the literature. *Surv Ophthalmol.* 2011;56:348–361.
- Jang TL, Erickson B, Medendorp A, et al. Comparison of donor site intraoral morbidity after mucosal graft harvesting for urethral reconstruction. *Urology.* 2005;66:716–720.
- Dublin N, Stewart LH. Oral complications after buccal mucosal graft harvest for urethroplasty. *BJU Int.* 2004;94:867–869.
- Nakamura T, Endo K, Cooper LJ, et al. The successful culture and autologous transplantation of rabbit oral mucosal epithelial cells on amniotic membrane. *Invest Ophthalmol Vis Sci.* 2003;44:106–116.