

Bilateral Candida Keratitis in A Patient with Transconjunctival Substance Abuse

Mehrdad Mohammadpour, MD¹ • Farid Kalantari, MD² • Mahmood Jabbarvand, MD³
Hassan Hashemi, MD⁴ • Nasser Karimi, MD, MPH⁵

Abstract

Purpose: To report an unusual case of bilateral Candida keratitis in a young drug abuser

Case report: A 19-year-old man sought medical care for his left eye redness, pain and photophobia. On slit-lamp examination a well-defined paracentral exudative corneal ulcer was observed. Smear from the corneal ulcers contained pseudohyphae and accordingly a routine regime of antifungal therapy (topical drop of Amphotericin-B 0.15% q1h beside out-patient daily follow-up) was commenced. Although the signs and symptoms improved initially, the corneal ulcer grew even larger in the third day of treatment and the contralateral cornea also began to show preliminary signs of fungal infection. Further work-ups revealed that his bilateral Candida keratitis had happened in association with an unusual route of drug abuse (transconjunctival heroin abuse). Clinical response was achieved by additional topical Voriconazol (1% q1h) and systemic Fluconazol (200 mg bid).

Conclusion: Candida Keratitis in the context of previous drug abuse and the presence of bilateral keratoconjunctivitis beside kissing conjunctival lesions may serve as diagnostic clues for this very rare condition.

Keywords: Candida Keratitis, Drug Abuse, Transconjunctival Route

Iranian Journal of Ophthalmology 2012;24(1):71-74 © 2012 by the Iranian Society of Ophthalmology

-
1. Assistant Professor of Ophthalmology, Eye Research Center, Farabi Eye Hospital, Tehran University of Medical Sciences, Tehran, Iran
 2. Resident in Ophthalmology, Eye Research Center, Farabi Eye Hospital, Tehran University of Medical Sciences, Tehran, Iran
 3. Professor of Ophthalmology, Eye Research Center, Farabi Eye Hospital, Tehran University of Medical Sciences, Tehran, Iran
 4. Noor Ophthalmology Research Center, Noor Eye Hospital, Tehran, Iran and Professor of Ophthalmology, Eye Research Center, Farabi Eye Hospital, Tehran University of Medical Sciences, Tehran, Iran
 5. MD-MPH Student, Eye Research Center, Farabi Eye Hospital, Tehran University of Medical Sciences, Tehran, Iran

Received: October 30, 2011

Accepted: February 29, 2012

Correspondence to: Mehrdad Mohammadpour, MD

Assistant Professor of Ophthalmology, Eye Research Center, Farabi Eye Hospital, Tehran University of Medical Sciences, Tehran, Iran,
Email: mahammadpour@yahoo.com

There is no financial interest for the authors in any methods or materials mentioned in this article.

Introduction

Candida keratitis is best considered as an opportunistic infection of a compromised cornea that is often initially misdiagnosed, and despite antifungal therapy, occasionally requires corneal grafting. The uncompromised cornea seems adequately resistant to the small inocula to which urban citizens are ordinarily exposed. However significant inocula of fungi may be introduced into the corneal stroma in agricultural settings or associated with soft contact lens wear.¹ Known predisposing conditions for Candida keratitis include ocular surface disorders, chronic keratopathy, or toxicity, corneal graft, recent trauma or recent topical treatment.² We report a case of bilateral Candida keratitis associated with unusual transconjunctival route of drug abuse. To the best of our knowledge, this is the first report of bilateral Candida keratitis in a patient with transconjunctival substance abuse in the literature.

Case report

A 19-year-old man came to emergency department of Farabi Eye Hospital with the complaint of left eye redness, pain and photophobia for 4 days. He gave no history of contact lens wearing, ocular surface trauma, or being on any medication (neither topical nor systemic). He solely attributed his symptoms to habitual eyelids rubbing. Relying on the history, he was an occasional alcohol and substance abuser mostly crack (a misnomer in the region for condensed heroin).

On his initial eye examination, visual acuity (VA) was $^{10}/_{10}$ and $^9/_{10}$ in the right and left eyes respectively. On slit-lamp examination, conjunctival injection and a well-defined paracentral exudative corneal ulcer with hypopyon was observed in the left eye. Right eye examination was unremarkable. Smear and culture was obtained. In this step, smear results revealed pseudomycelium/yeast, and accordingly a routine treatment of antifungal therapy [topical drop of Amphotericin-B (0.15%) every 1 h] beside an out-patient daily follow-up, was planned, considering a fungal corneal ulcer. By the next day, relative improvement was achieved both objectively

and subjectively. The patient was absent for next visit. The following day, however, he returned to the clinic complaining of worsening symptoms. On slit-lamp examination, the left corneal ulcer and Hypopyon was found to get worsened. Surprisingly, the right eye was noted to be injected and slit-lamp examination revealed 2 small foci of stromal infiltration and fine overlying epithelial defects (Figure 1). Further slit-lamp examination disclosed epithelial abrasions on nasal side of bulbar and palpebral conjunctiva (lower lid) (Figure 2). No Fluorescein strip was applied directly into the inferior cul-de-sac. Fluorescein staining was done by introducing sterile artificial tear drops (stained over a fluorescein strip) into the inferior cul-de-sac.

Microbiology unit at the third day reported a culture growth consistent with Candida albicans. In this situation, considering progressive nature of the disease and the patient's poor compliance, patient was admitted. Subsequently specimens for smear/culture were obtained from both eyes and the antifungal regimen was upgraded to topical Amphotericin B (0.15% q1h), topical Voriconazol (1% q1h) and systemic Fluconazol (200 mg bid). In the following days, subjective complaints dramatically improved, while epithelial defect size and hypopyon was regressed more gradually. The smear/culture results for both eyes reconfirmed Candida Albicans as the source of infection (Figure 3). Viral serology (HBV, HIV and HCV) was unremarkable.

Besides, while he was taken care of in the ward, the nursing staff registered his unauthorized smoking and suspicious drug-abuse behavior. In consultation sessions, he admitted to drug-abuse. Although we initially faced his denial, he ultimately confirmed that he would take the so-called "Crack" via mucosal absorption in inferior cul-de-sac. Further consultations along with regulated antifungal medication, led to dramatic clinical improvement. By the end of the 2nd week, complete resolution of corneal ulcers was achieved, albeit with residual scars. Conjunctival scarring didn't ensue.

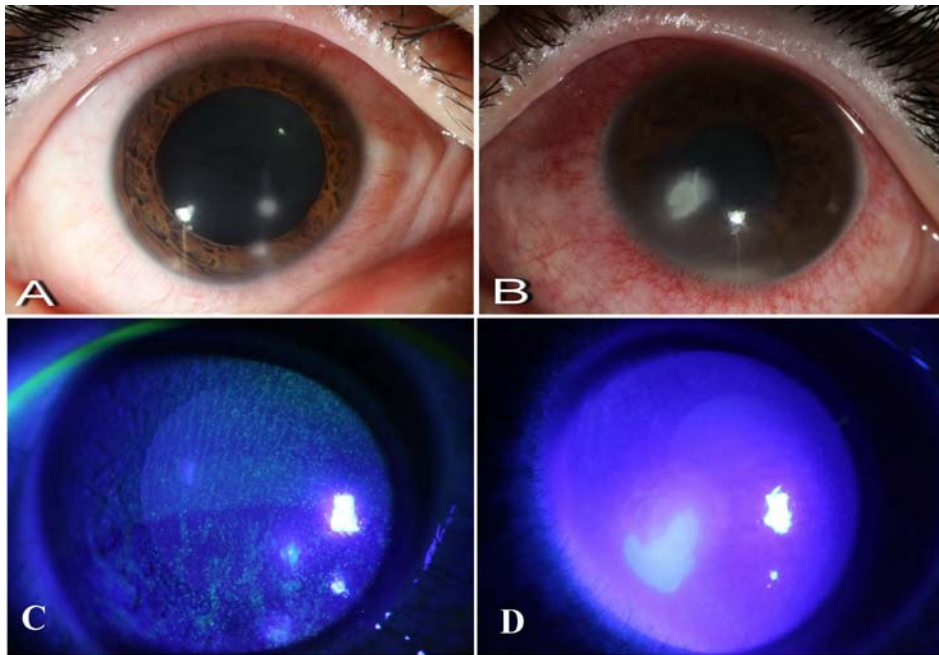


Figure 1. Slit-lamp examination and fluorescein staining in the 3rd day. A: Two small foci of stromal infiltrations is seen in the right eye. B: Corneal ulcer accompanied by hypopyon in the left eye. C: Minimal staining over the lesions in the right eye D: Distinct staining of epithelial defect in the left eye

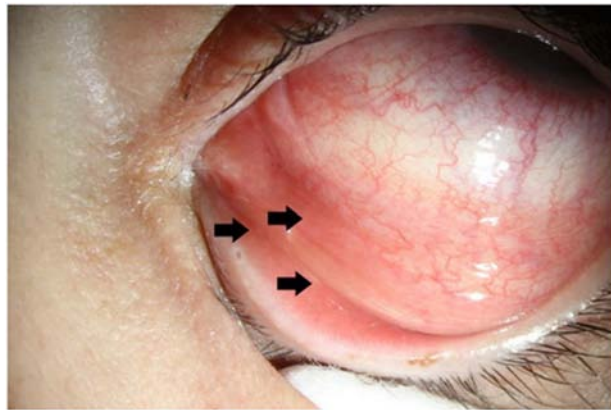


Figure 2. Local irritation and epithelial erosion was noted in the left eye conjunctiva

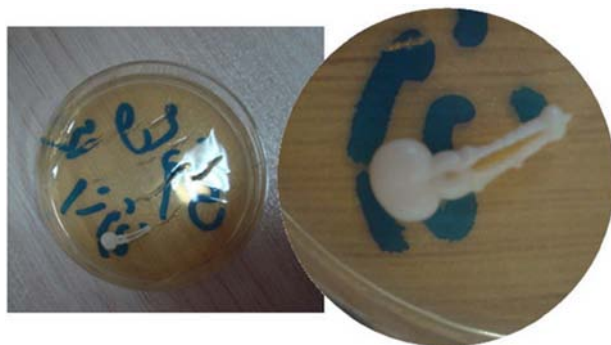

Figure 3. Culture media of Sabouraud agar showing *Candida albicans* colonies

Discussion

Bilateral candida keratitis is a very rare report in the scientific literature. To study clinical characteristics of Candida keratitis Sun et al reviewed records of all patients who visited an academic-based eye center in Houston, Texas in a 30-year period. Among 27 patients reported in the case series only one of them had bilateral infection.² Bilateral Candida keratitis has been reported by Muallem et al (following LASIK)³ and Höflin-Lima et al (following therapeutic contact lens use in a patient who had undergone bilateral penetrating keratoplasty).⁴ As far as we are aware of, this is the first report of bilateral Candida keratitis secondary to transconjunctival drug abuse. Transconjunctival heroin abuse was reported recently as an unusual route of drug abuse⁵ reporting a young drug addict with bilateral atypical conjunctival lesions with no epithelial defects of either cornea. The authors concluded that drug abuse should be considered in diagnostic approach to an unusual presentation of ocular disease. It is well-known that among drug users cocaine addicts are at risk of corneal complications

including superficial punctate keratitis, epithelial defects, ulcers, and secondary infections.⁶ Vigorous eye rubbing, retrograde passage through the nasolacrimal duct during snuffing as well as substance smoke has been postulated as probable routes of cocaine's direct contact with external eye surface.⁷⁻⁹ Our patient used inferior cul-de-sac as a mucosal port of drug delivery for condensed purified heroin. Kissing nature of conjunctival lesions (involving both bulbar and palpebral conjunctiva) was evident in this patient.

Conclusion

To the best of our knowledge this is the first report of bilateral Candida keratitis in a patient with transconjunctival substance abuse in the literature. It seems that transconjunctival drug abuse should be added to the list of predisposing factors of bilateral keratoconjunctival pathology. Clues to potential drug abuse of any kind and the presence of atypical keratoconjunctival lesions are probably the best predictive factors of this rare condition.

References

1. Vaughan D, Asbury T. Vaughan & Asbury's general ophthalmology, 17 ed. New York: Lange Medical Books/McGraw-Hill, 2007.
2. Sun RL, Jones DB, Wilhelmus KR. Clinical characteristics and outcome of Candida keratitis. *Am J Ophthalmol* 2007;143(6):1043-5.
3. Muallem MS, Alfonso EC, Romano AC, et al. Bilateral Candida parapsilosis interface keratitis after laser in situ keratomileusis. *J Cataract Refract Surg* 2003;29(10):2022-5.
4. Höflin-Lima AL, Roizenblatt R. Therapeutic contact lens-related bilateral fungal keratitis. *CLAO J* 2002;28(3):149-50.
5. Alipour F, Hashemi H, Piri N, Asghari H. Ocular manifestations of transconjunctival heroin abuse: a case report of an unusual route of substance abuse. *Cornea* 2010;29(1):110-2.
6. Firth A. Editorial: ocular side effects of drug use. *Can J Ophthalmol* 2006;41(2):140-6.
7. Sachs R, Zigelbaum BM, Hersh PS. Corneal complications associated with the use of crack cocaine. *Ophthalmology* 1993;100(2):187-91.
8. Mohammadpour M. Progressive corneal vascularization caused by graft-versus-host disease. *Cornea* 2007;26(2):225-6.
9. Mohammadpour M, Javadi MA. Keratitis associated with multiple endocrine deficiency. *Cornea* 2006;25(1):112-4.