

# Characteristics of Advanced Stages of Retinopathy of Prematurity

S Zeinab Mousavi, MD<sup>1</sup> • Mohammad Riazi Esfahani, MD<sup>2</sup> • Ramak Roohipoor, MD<sup>3</sup>  
Mahmoud Jabbarvand, MD<sup>2</sup> • Leila Ghalichi, MD, PhD<sup>4</sup> • Mehdi Nili Ahmadabadi, MD<sup>2</sup>  
Fariba Ghassemi, MD<sup>3</sup> • Zahra Aalami Harandi, MD<sup>2</sup> • Reza Karkhaneh, MD<sup>5</sup>

---

## Abstract

**Purpose:** To evaluate the incidence and risk factors of severe visual impairment and retinopathy of prematurity (ROP)-related blindness in a tertiary eye hospital in Iran

**Methods:** In a cross-sectional study, clinical data of premature infants screened for ROP in Farabi Eye Hospital during 2003-2007 were reviewed. Characteristics of advanced stages of ROP (stage 4 or 5) were determined and compared to other stages of ROP.

**Results:** Among 1053 infants, 380 (36.1%) had ROP, 91 infants (8.6%) had advanced stages of ROP in at least one eye (none of them had a history of previous ROP screening); 40 of them had bilateral stage 5. The mean gestational age (GA) and birth weight (BW) in infants with advanced ROP were 28.3±2.3 (24-35) weeks and 1267±398 (450-2600) g, respectively. 74.7% of infants with advanced ROP had been examined after 9 weeks of infantile age. Only 23.1% (<sup>21</sup>/<sub>91</sub>) had recommendation for eye examination by their neonatologists. Lower GA was the independent risk factor of developing advanced ROP (P< 0.001).

**Conclusion:** We observed a high incidence of advanced ROP (stage 4 and or 5) in our settings; most of them were not referred for screening examination during the first few weeks and had delayed eye examination. Among the possible risk factors, GA was the only factor related with development of advanced ROP.

**Keywords:** Blindness, Visual Impairment, Retinopathy of Prematurity

*Iranian Journal of Ophthalmology 2010;22(2):19-24 © 2010 by the Iranian Society of Ophthalmology*

---

- 
1. Research Assistant, Eye Research Center, Farabi Eye Hospital, Tehran University of Medical Sciences
  2. Associate Professor of Ophthalmology, Eye Research Center, Farabi Eye Hospital, Tehran University of Medical Sciences
  3. Assistant Professor of Ophthalmology, Eye Research Center, Farabi Eye Hospital, Tehran University of Medical Sciences
  4. PhD Student, Department of Epidemiology, School of Public Health, Tehran University of Medical Sciences
  5. Professor of Ophthalmology, Eye Research Center, Farabi Eye Hospital, Tehran University of Medical Sciences

Received: November 8, 2009

Accepted: May 27, 2010

Correspondence to: Reza Karkhaneh, MD

Eye Research Center, Farabi Eye Hospital, Tehran, Iran, Tel:+98 21 55414941-6, Email: karkhane@sina.tums.ac.ir

## Introduction

Childhood blindness can cause significant loss of productivity for the child and society; therefore, control of childhood blindness is a priority of WHO's vision 2020 program.<sup>1</sup> It has been estimated that about 75% of the total 1.4 million blind children live in developing countries.<sup>1</sup> Retinopathy of prematurity (ROP) is one of the potentially preventable causes of childhood blindness<sup>2</sup> which afflicts 50,000 infants each year.<sup>3</sup> Based on the infant mortality rate in our country, it is predicted that Iran is one of the countries with high risk of severe visual impairment due to ROP and more data about it is needed.<sup>4,5</sup>

Many studies have addressed the natural course and risk factors of ROP<sup>6-10</sup>; some have focused on risk factors of severe ROP<sup>11-15</sup> and some have assessed risk factors of progression into advanced ROP and retinal detachment after treatment.<sup>16-18</sup> However, it is not yet clear what causes the infant to have regressed ROP, and what causes the infant to progress into retinal detachment; thus, the question remains that if there is any specific risk factor for late stages of ROP. We undertook this study to report characteristics of advanced ROP in a tertiary eye hospital in Iran to provide preliminary evidence about visual impairment and blindness due to ROP in our country, and to assess risk factors of late stages of ROP.

## Methods

The study was conducted in pediatric retina and vitreous division of Farabi Eye Hospital, affiliated with Tehran University of Medical Sciences, during October 2003 to November 2007. Data of premature infants screened for ROP were retrieved from infants' medical records. The retrieved data were: the result of complete eye exam (according to the international classification of ROP<sup>19</sup>), infantile age at first eye exam, neonatologist's recommendation for eye examination, birth weight (BW), gestational age (GA), neonatal age, gender, singleton or multiple gestations, oxygen therapy, mechanical ventilation, respiratory distress syndrome, phototherapy, intraventricular hemorrhage, necrotizing enterocolitis, sepsis (blood culture positive) and blood transfusion. Data of the last 9 factors were available as yes/no and were analyzed as dichotomous variables. The statistical

program of SPSS 15 was used for database analysis. The chi square test and independent sample t-test were employed to evaluate potential dichotomous and continuous risk factors respectively.

Definition In this study:

- **Mild ROP** was defined as ROP that needed no treatment.
- **Severe ROP** was defined as ROP that needed treatment (according to the criteria of early treatment for retinopathy of prematurity).<sup>20</sup>
- **Advanced ROP** was defined as stage 4 or 5 of ROP in at least one eye.
- **Visual impairment** was defined as advanced ROP less than bilateral stage 5.

Bilateral stage 5 of disease was considered as **blindness**.

## Results

During the period of the study, 1060 premature infants were examined, 7 were excluded because their complete eye examination result was not available. From 1053 infants, 380 (36.1%) had ROP, 91 of them (8.6%) were in advanced stages of ROP and 3.8% (<sup>40</sup>/<sub>1053</sub>) had bilateral stage 5 of ROP. From 91 infants with advanced ROP, 53 (58.2%) were males; 43 (47.3%) were born in Tehran and the rest were born in other cities and none of them had a history of previous ROP screening. The mean GA and BW of infants with advanced ROP are compared with other stages of ROP in table 1. The mean infantile age at first ophthalmic examination was 27.5±31.7 weeks in advanced ROP while it was 6.7±2.9 weeks in infants with other stages of ROP, the difference was statistically significant (P<0.001). The first eye exam of 74.7% (<sup>68</sup>/<sub>91</sub>) of infants with advanced ROP was done after 9 weeks of infantile age. Only 21 of 91 infants (23.1%) had recommendation for eye examination during the first few weeks by their neonatologists, and 33 (36.32%) did not have it (the reason of their attendance for retinal exam is summarized in table 2). The data was unavailable in the rest of 37 infants.

Seven of forty infants (17.5%) with stage 5 in both eyes had neonatal recommendation for eye examination before 9 weeks of

neonatal age and 17 (42.5%) did not have this recommendation. Two of them (5%) were recommended by another physician to have eye examination when they were older than 9 weeks.

In statistical analyses, only lower GA was identified as risk factor of having advanced ROP compared to other stages of ROP ( $P<0.001$ ), while there was no significant association between advanced ROP and other factors. Using ROP grouping of: none,

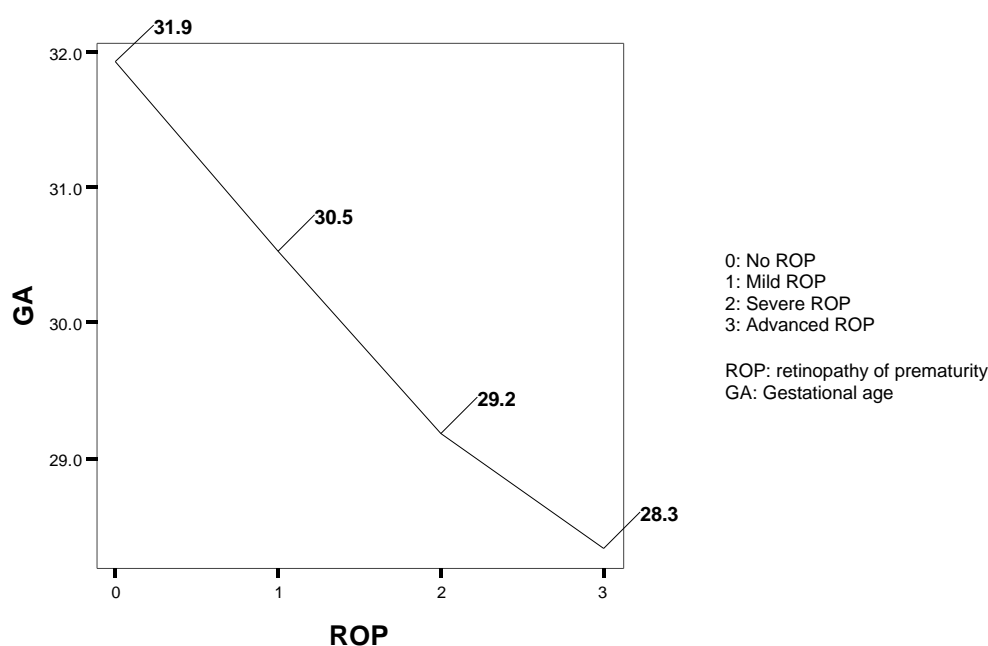
mild, severe and advanced; a linear correlation with GA was seen as is shown in figure 1. The difference of GA among these 4 group was statistically significant ( $P<0.001$ ). Using the same ROP grouping, BW showed a linear correlation with ROP except for advanced ROP (Figure 2). The difference of BW among the first three groups was statistically significant ( $P<0.02$ ); however, the difference between severe and advanced ROP was not significant ( $P=0.9$ ).

**Table 1.** Statistical analysis of the role of gestational age and birth weight on advanced retinopathy of prematurity

Stages of ROP	Mean gestational age (Minimum-Maximum)	Mean birth weight (Minimum-Maximum)	P-value
Advanced retinopathy of prematurity	28.3±2.3 (24-35) weeks	1267±398 (450-2600) g	<0.001
Other stages of retinopathy of prematurity	29.8±2.3 (24-36) weeks	1333±379 (560-2800) g	>0.05

**Table 2.** Reason for attending for eye exam in infants without recommendation for eye examination by their neonatologist

Reason	No.
Parental notice to their infant's low vision	9 (27.3%)
Parental notice to other ophthalmic problems	4 (12.1%)
Being recommended by another physician when they were older than 9 weeks	7 (21.2%)
Being recommended by neonatologist to seek care at 3rd month	1 (3.0%)
Unavailable data	12 (36.4%)
Total	33



**Figure 1.** Correlation between retinopathy of prematurity and gestational age

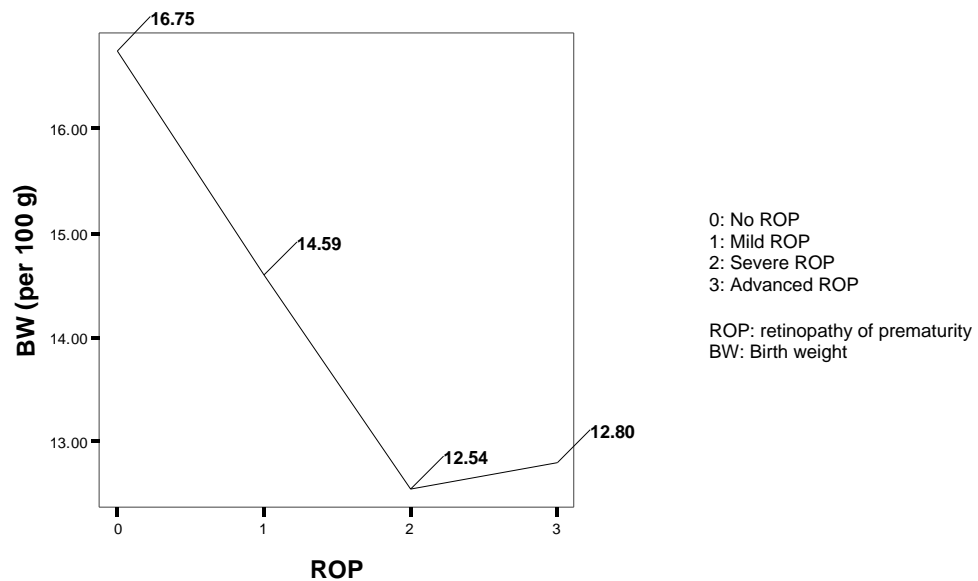


Figure 2. Correlation between retinopathy of prematurity and birth weight

## Discussion

In our study, the incidence of advanced ROP (stage 4 or 5) was 8.6% (N=91). This number consists of 3.8% of bilateral stage 5 (N=40) and 2.3% (N=24) of unilateral stage 5; these infants were considered as visually impaired or blind. Although high incidence of stage 4 or 5 of ROP has recently been reported from a tertiary eye hospital in China,<sup>22</sup> most of the other recent studies have not reported the same findings. For example, one study has reported the incidence of advanced ROP to be 1.8% in infants born below 27 weeks of GA,<sup>23</sup> and many other studies have not reported any advanced ROP in their settings,<sup>11,24,25</sup> specially in more mature infants.<sup>26</sup> While better control of risk factors is a reason,<sup>5</sup> performing regular screening programs which results in identification of ROP before formation of the advanced disease is another reason. However, the results of this study showed that we have a high percent of infants who come too late for retinal exam. The study from China also reported the same results about the time of screening exams,<sup>22</sup> whereas a report from New Zealand showed that only one of 85 infant (1.2%) was examined after 9 weeks (at 11 weeks) and had stage 4 ROP.<sup>27</sup>

In a study from our center, during 1999-2002,<sup>4</sup> the infants with severe visual impairment due to ROP had a first eye

examination at  $25.1 \pm 13.8$  weeks, and only 36% of them had neonatologists' recommendation for eye examination. Comparison of these data with the results of the present study ( $27.5 \pm 31.7$  and 23.1% respectively), may show that there has been no major improvement in the referral situation during the past decade in our country. This emphasizes the role of implementing a national ROP screening protocol, and to educate ophthalmologists, neonatologists and parents about this sight-threatening disease.

Presentation of ROP in infants with higher GA or BW in this study, suggests that there should be set a wider screening criteria for detecting premature infants with ROP in Iran, since UK<sup>21</sup> and AAPOS<sup>28</sup> screening guidelines may not be applicable in our society.

In our study, lower GA was related with developing ROP, in addition, it was related with having severe or advanced ROP. Many studies have shown the role of lower GA in developing ROP<sup>29</sup>; also there are studies which have shown the role of lower GA on progression of ROP to its severe form.<sup>11,14</sup> BW also had significant correlation with development of ROP, the difference between mean BW in mild and severe ROP was also significant. However, BW had no significant difference between severe and advanced

ROP. Maybe because the infants usually gain a little weight in lower GAs, and they add more weight only in later GAs; thus, we can not see statistical difference in BW of infants with different stages of ROP who were born in lower GAs.

This was a unit-based retrospective study and there were some limitations in it. First, the incidence of advanced ROP in our study may not be representative of all of our country, as not all the infants eligible for ROP screening are screened in Iran, due to the lack of a uniformed guideline for their screening. Another reason for non-representation of our data is that some patients are referred to Farabi Eye Hospital just because they have advanced ROP; thus, the observed percent of advanced ROP is increased. Therefore, larger

population-based studies about ROP are needed in Iran.

### **Conclusion**

In summary, we observed a high incidence of ROP related visual impairment and blindness. Many of these infants did not have recommendation for eye examination and were examined too late. These findings indicate that we need a national screening program for retinopathy of prematurity in our country.

### **Funding**

This project was supported by a grant from Tehran University of Medical Sciences under grant No. 19952.

### **References**

1. Gilbert C, Foster A. Childhood blindness in the context of VISION 2020--the right to sight. *Bull World Health Organ* 2001;79(3):227-32.
2. Clemett R, Darlow B. Results of screening low-birth-weight infants for retinopathy of prematurity. *Curr Opin Ophthalmol* 1999;10(3):155-63.
3. Saugstad OD. Oxygen and retinopathy of prematurity. *J Perinatol* 2006;26 Suppl 1:S46-50.
4. Karkhaneh R, Riazi Esfahani M, Lashay AR, Chams H. A survey on visual impairment and blindness in children from retinopathy of prematurity. *Iranian Journal of ophthalmology* 2003;15(2):101-5.
5. Gilbert C. Retinopathy of prematurity: a global perspective of the epidemics, population of babies at risk and implications for control. *Early Hum Dev* 2008;84(2):77-82.
6. Fleck BW, McIntosh N. Pathogenesis of retinopathy of prematurity and possible preventive strategies. *Early Hum Dev* 2008;84(2):83-88.
7. Karna P, Muttineni J, Angell L, Karmaus W. Retinopathy of prematurity and risk factors: a prospective cohort study. *BMC Pediatr* 2005;5(1):18.
8. Friling R, Axer-Siegel R, Hersocovici Z, et al. Retinopathy of prematurity in assisted versus natural conception and singleton versus multiple births. *Ophthalmology* 2007;114(2):321-4.
9. Darlow BA, Hutchinson JL, Henderson-Smart DJ, et al. Prenatal risk factors for severe retinopathy of prematurity among very preterm infants of the Australian and New Zealand Neonatal Network. *Pediatrics* 2005;115(4):990-6.
10. Karkhaneh R, Mousavi SZ, Riazi-Esfahani M, et al. Incidence and risk factors of retinopathy of prematurity in a tertiary eye hospital in Tehran. *Br J Ophthalmol* 2008;92(11):1446-9.
11. Akkoyun I, Oto S, Yilmaz G, et al. Risk factors in the development of mild and severe retinopathy of prematurity. *J AAPOS* 2006;10(5):449-53.
12. Todd D, Kennedy J, Roberts V, John E. Risk factors in progression beyond stage 2 retinopathy of prematurity. *Aust N Z J Ophthalmol* 1990;18(1):57-60.
13. Rabinowitz MP, Grunwald JE, Karp KA, et al. Progression to severe retinopathy predicted by retinal vessel diameter between 31 and 34 weeks of postconception age. *Arch Ophthalmol* 2007;125(11):1495-500.
14. Hagadorn JI, Richardson DK, Schmid CH, Cole CH. Cumulative illness severity and progression from moderate to severe retinopathy of prematurity. *J Perinatol* 2007;27(8):502-9.
15. Yang MB, Donovan EF, Wagge JR. Race, gender, and clinical risk index for babies (CRIB) score as predictors of severe retinopathy of prematurity. *J AAPOS* 2006;10(3):253-61.

16. Bourla DH, Gonzales CR, Valijan S, et al. Association of systemic risk factors with the progression of laser-treated retinopathy of prematurity to retinal detachment. *Retina* 2008;28(3 Suppl):S58-64.
17. Kim MJ, Kim SJ, Yu YS. The risk for retinal detachment associated with hemorrhages pre- and postlaser treatment in retinopathy of prematurity. *Retina* 2008;28(10):1451-7.
18. Coats DK. Retinopathy of prematurity: involution, factors predisposing to retinal detachment, and expected utility of preemptive surgical reintervention. *Trans Am Ophthalmol Soc* 2005;103:281-312.
19. An international classification of retinopathy of prematurity. Prepared by an international committee. *Br J Ophthalmol* 1984;68(10):690-7.
20. Early Treatment For Retinopathy Of Prematurity Cooperative Group. Revised indications for the treatment of retinopathy of prematurity: results of the early treatment for retinopathy of prematurity randomized trial. *Arch Ophthalmol* 2003;121(12):1684-94.
21. Wilkinson AR, Haines L, Head K, Fielder AR. UK retinopathy of prematurity guideline. *Early Hum Dev* 2008;84(2):71-4.
22. Chen Y, Li X. Characteristics of severe retinopathy of prematurity patients in China: a repeat of the first epidemic? *Br J Ophthalmol* 2006;90(3):268-71.
23. Austeng D, Källén KB, Ewald UW, et al. Incidence of retinopathy of prematurity in infants born before 27 weeks' gestation in Sweden. *Arch Ophthalmol* 2009;127(10):1315-9.
24. Manzoni P, Farina D, Maestri A, et al. Mode of delivery and threshold retinopathy of prematurity in pre-term ELBW neonates. *Acta Paediatr* 2007;96(2):221-6.
25. Binkhathlan AA, Almahmoud LA, Saleh MJ, Srungeri S. Retinopathy of prematurity in Saudi Arabia: incidence, risk factors, and the applicability of current screening criteria. *Br J Ophthalmol* 2008;92(2):167-9.
26. Ahmed MA, Duncan M, Kent A, NICUS Group. Incidence of retinopathy of prematurity requiring treatment in infants born greater than 30 weeks' gestation and with a birthweight greater than 1250 g from 1998 to 2002: a regional study. *J Paediatr Child Health* 2006;42(6):337-40.
27. Darlow BA, Clemett RS. Retinopathy of prematurity: screening and optimal use of the ophthalmologist's time. *Aust N Z J Ophthalmol* 1990;18(1):41-6.
28. Screening examination of premature infants for retinopathy of prematurity. Section on Ophthalmology American Academy of Pediatrics; American Academy of Ophthalmology; American Association for Pediatric Ophthalmology and Strabismus. *Pediatrics* 2006;117(2):572-6.
29. Lermann VL, Fortes Filho JB, Procianoy RS. The prevalence of retinopathy of prematurity in very low birth weight newborn infants. *J Pediatr (Rio J)* 2006;82(1):27-32.
30. Shah VA, Yeo CL, Ling YL, Ho LY. Incidence, risk factors of retinopathy of prematurity among very low birth weight infants in Singapore. *Ann Acad Med Singapore* 2005;34(2):169-78.