

Correlation between Filtering Bleb Clinical Morphology, Anterior Segment Optical Coherence Tomography Findings, and Intraocular Pressure

Ghasem Fakhraie, MD¹ • Sedigheh Kohansal, MD² • Yadollah Eslami, MD¹
Mahmoud Jabbarvand, MD¹ • Reza Zarei, MD¹ • Seyed Mohsen Rafizadeh, MD²
Mohammad Bagher Rajabi, MD² • Mohammad Reza Fallah, MD¹ • Sasan Moghimi, MD¹

Abstract

Purpose: To evaluate usefulness of anterior segment optical coherence tomography (AS-OCT) in evaluation of filtering bleb functionality and to correlate its findings with clinical bleb examination

Methods: In this cross-sectional, descriptive study 55 eyes with apparently functional bleb were evaluated. Following a comprehensive ophthalmic examination, filtering bleb grading was performed based on Indiana Bleb Appearance Grading Scale (IBAGS). The bleb was then imaged using AS-OCT. Two radial and tangential scans were obtained.

Results: The mean age was 57.69±12.47 years and 29 cases (53%) were female. The mean number of glaucoma medication and intraocular pressure (IOP) were 0.45±0.71 and 14.35±4.67 mmHg, respectively. On AS-OCT examination, the mean bleb height, bleb wall thickness, internal cavity height, posterior extension of the internal cavity were 1.5±0.47 mm, 1±0.4 mm, 0.59±0.28 mm, and 3.15±1.26 mm, respectively. The internal reflectivity was high in 15 cases (27%) and low in 40 cases (73%). There was a positive correlation between the bleb height, bleb wall thickness, and internal cavity height on AS-OCT and IOP. Also, a negative correlation between the posterior extension of the internal cavity and IOP was noted. There was also a positive correlation between the higher IOP and a high internal reflectivity. There has also been a positive correlation between the bleb height at IBAGS and bleb reflectivity at AS-OCT. We also found that there was a positive correlation between the bleb vascularity at IBAGS and internal reflectivity at AS-OCT.

Conclusion: AS-OCT seems to be a useful device in evaluation of filtering bleb function. It yields valuable information regarding the internal bleb structures, and its findings are correlated with clinical examination of filtering bleb.

Keywords: Anterior Segment Optical Coherence Tomography, Filtering Bleb, Glaucoma

Iranian Journal of Ophthalmology 2011;23(4):21-28 © 2011 by the Iranian Society of Ophthalmology

1. Associate Professor of Ophthalmology, Eye Research Center, Farabi Eye Hospital, Tehran University of Medical Sciences, Tehran, Iran

2. Resident in Ophthalmology, Eye Research Center, Farabi Eye Hospital, Tehran University of Medical Sciences, Tehran, Iran

Received: April 6, 2011

Accepted: September 12, 2011

Correspondence to: Sasan Moghimi, MD

Associate Professor of Ophthalmology, Eye Research Center, Farabi Eye Hospital, Tehran University of Medical Sciences, Tehran, Iran, Tel:+98 21 55416134, Email: sasanimii@yahoo.com

Disclosure: None of the authors has any proprietary or financial interest in the products mentioned in this article. This study was supported by a grant from the Tehran University of Medical Science (TUMS).

Introduction

Since its introduction,¹ guarded filtering surgery, or trabeculectomy, has been the surgical procedure of choice in medically uncontrolled glaucoma patients.² A successful result of trabeculectomy is a diffuse, moderately elevated filtering bleb with numerous epithelial microcysts; but a failed bleb is either a flat bleb or a circumscribed, elevated, cystic, and encapsulated one with abnormal conjunctival vascularization.^{3,4}

A careful slit-lamp examination is important in evaluation of filtering bleb function and recognizing the signs of early bleb failure. Two major objective bleb grading systems, including the Indiana Bleb Appearance Grading Scale (IBAGS) and the Moorfields Bleb Grading System (MBGS) have been introduced for clinical evaluation and classification of filtering blebs.^{5,6} However, bleb evaluation merely based on slit-lamp examination has its own limitations; among which is the subjective nature of these methods. More recently, anterior segment optical coherence tomography (AS-OCT) has been introduced as a useful imaging device in objective evaluation of filtering blebs. AS-OCT provides a high resolution cross-sectional optical imaging of the anterior segment structures via a noninvasive and noncontact procedure, and can provide internal visualization of the blebs.⁷⁻¹³

The main objective of this study was to evaluate the usefulness of AS-OCT in evaluation of apparently functional filtering blebs, to find further criteria for filtering bleb functionality, and to investigate any association between intraocular pressure (IOP), bleb morphology, and AS-OCT findings.

Methods

In this cross-sectional, descriptive study, 55 eyes of 55 patients that had undergone trabeculectomy at the glaucoma service of Farabi Eye Hospital, Tehran University of Medical Sciences, Tehran, Iran were examined from January 2010 to December 2010. Ethics approval was obtained from the local Institutional Review Board. All patients consented to this study and underwent an enrollment interview. Only patients with apparently functional blebs were included. Exclusion criteria were flat bleb, occluded

internal ostium, surgery-examination interval time less than 4 months, retrabeculectomy, other ocular surgeries, poor patient cooperation, and severe systemic diseases.

Each patient underwent a comprehensive ophthalmic examination including best corrected visual acuity (BCVA) examination (Snellen chart), IOP measurement (Goldmann applanation tonometer) and funduscopy. Patients' gender, age, number of glaucoma medications, and the elapsed time following the surgery were also noted.

IBAGS system was used for clinical bleb grading by a single researcher (Gh. F.). The method of bleb grading using IBAGS has previously been well described. Briefly, patient was asked to look down on slit-lamp examination and the upper lid was gently elevated without any pressure on the globe or bleb. Bleb characteristics, including its height, vascularity, extension, and Seidel test were recorded and scaled based on standard photographs.⁵ Bleb height was graded, from H₀ (flat bleb without visible elevation) to H₃ (high bleb). Bleb extent was graded from E₀ (no visible bleb extent to less than 1 clock hour) to E₃ (extent equal to or greater than 4 clock hours). Bleb vascularity was graded from V₀ [avascular/white (no microcysts visible on slit-lamp examination)] to V₄ [extensive vascularity (vascular engorgement)]. Seidel test was graded from S₀ (no bleb leak) to S₂ [streaming aqueous egress visible within 5 seconds of application of fluorescein (diffuses or localized)]. The bleb was then imaged using AS-OCT (Carl Zeiss Meditec Inc., Dublin, CA) and one standard radial AS-OCT section perpendicular to the limbus (passing through the PI location), and also one transverse section (passing through the most extensive area of the bleb) were obtained (Figure 1). AS-OCT findings including bleb height, bleb wall thickness, posterior extension of the bleb internal cavity (the fluid filled cavity of the filtering bleb), internal cavity height, and internal reflectivity (reflectivity of the internal structures and wall of filtering bleb compared with surrounding structures) were noted and recorded (Figures 2, 3). Internal reflectivity was classified as high if the reflectivity of internal structure of the filtering bleb was similar to sclera and low if the reflectivity was less than sclera (Figures 3).

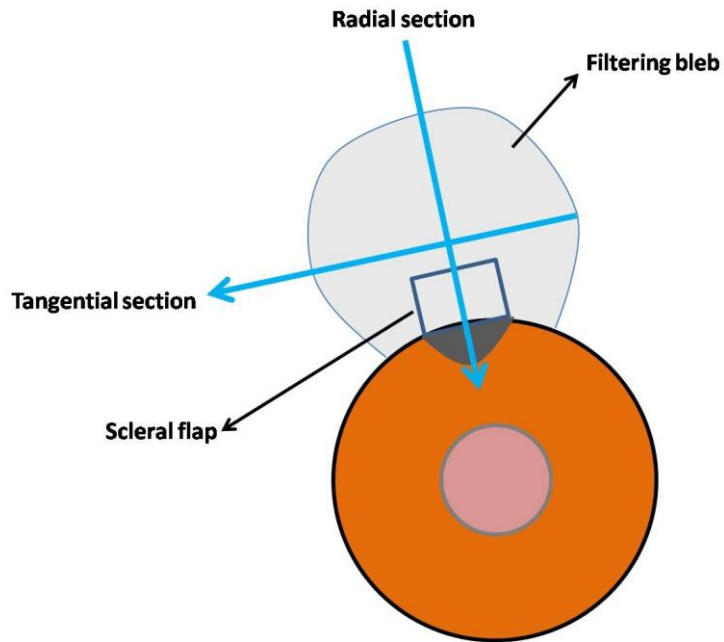


Figure 1. Schematic drawing shows how Optical Coherence Tomography scans were obtained.

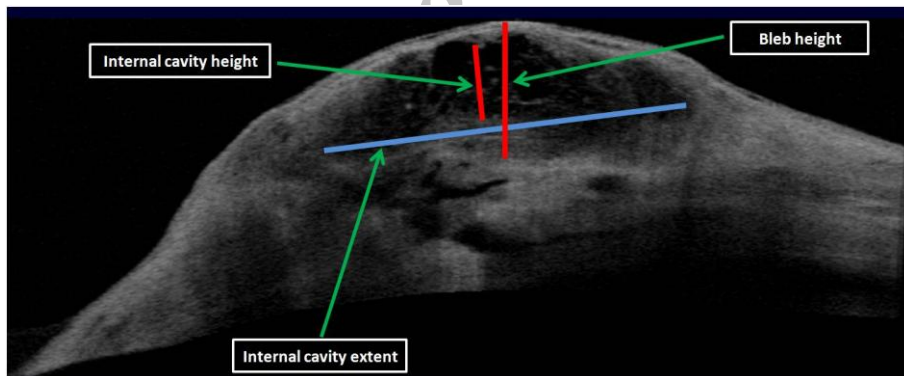


Figure 2. Variables measured with Optical Coherence Tomography.

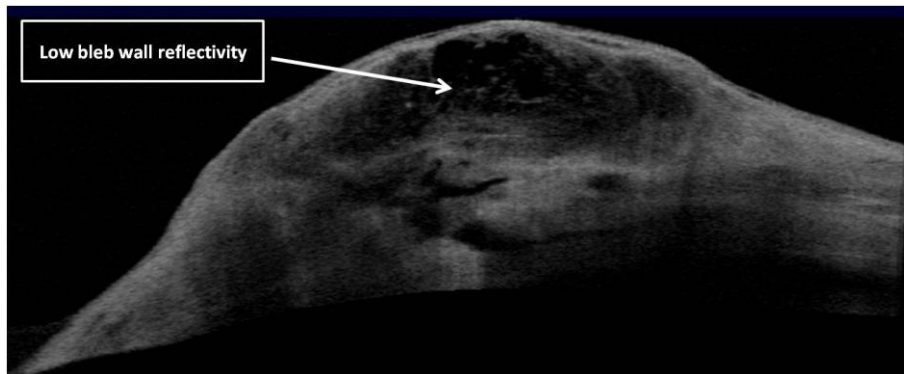


Figure 3. A filtering bleb shows low internal reflectivity.

Statistical analysis

Statistical analysis was performed using SPSS for Windows version 16 (SPSS Inc., Chicago, IL). The Pearson Product Moment Correlation Coefficient was used to evaluate any correlation between the two continuous variables. The Contingency Coefficient of Correlation was used to evaluate the correlation between the two categorical variables. For all measurements, a two-tailed test was used and a P value of <0.05 was considered significant for measured variables.

Results

A total of 55 eyes of 55 cases were included. Patients' baseline characteristics and demographics have been shown on Table 1.

The mean age was 57.69±12.47 years (range, 31-81) and 29 cases (53%) were female. The mean interval between the filtering surgery and current examination was 9.46±3.74 months (range, 4-22).

The mean number of glaucoma medication was 0.45±0.71 (range, 0-2), and the mean IOP was 14.35±4.67 mmHg (range, 5-22).

On AS-OCT examination, the mean bleb height was 1.5±0.47 mm (range, 0.75-2.61), and the mean bleb wall thickness was 1±0.4 mm (range, 0.31-1.88). The mean internal cavity height was 0.59±0.28 mm (range, 0.22-1.66) and the mean posterior extension of the internal cavity was 3.15±1.26 mm (range, 1.01-5.76) (Table 2). The internal reflectivity was high in 15 cases (27%) and low in 40 cases (73%).

There was a strong positive correlation between the bleb height on AS-OCT and IOP ($P<0.001$, $r=0.87$) (Figure 4). There was also a strong positive correlation between the bleb wall thickness and IOP ($P<0.001$, $r=0.91$) (Figure 5).

There has been a moderate positive correlation between the internal cavity height and IOP ($P<0.001$, $r=0.59$) (Figure 6).

On the other hand, a strong negative correlation between the posterior extension of the internal cavity and IOP was noted ($P<0.001$, $r=-0.94$) (Figure 7).

Also, there was a moderate positive correlation between the higher IOP and a high internal reflectivity ($P<0.001$, $r=0.69$). There has also been a moderate positive correlation

between the bleb height at IBAGS and bleb reflectivity at AS-OCT ($P<0.001$, $r=0.611$). We also found that there was a moderate positive correlation between the bleb vascularity at IBAGS and internal reflectivity at AS-OCT ($P<0.001$, $r=0.587$).

Table 1. Patients' baseline characteristics and demographics

Variable	Description
Age (years)	
Mean±SD	57.69±12.47
Range	31-81
Gender	
Female	29 (53%)
Male	26 (47%)
Surgery-exam interval (months)	
Mean±SD	9.46±3.74
Range	4-22
Glaucoma medication	
Mean±SD	0.45±0.71
Range	0-2
IOP (mmHg)	
Mean±SD	14.35±4.67
Range	5-22
IOP: Intraocular pressure	

Table 2. Anterior segment optical coherence tomography measured parameters

Variable	Description
Bleb height (mm)	
Mean±SD	1.5±0.47
Range	0.75-2.61
Bleb wall thickness (mm)	
Mean±SD	1±0.4
Range	0.31-1.88
Internal cavity height (mm)	
Mean±SD	0.59±0.28
Range	0.22-1.66
Posterior extension of internal cavity	
Mean±SD	3.15±1.26
Range	1.01-5.76

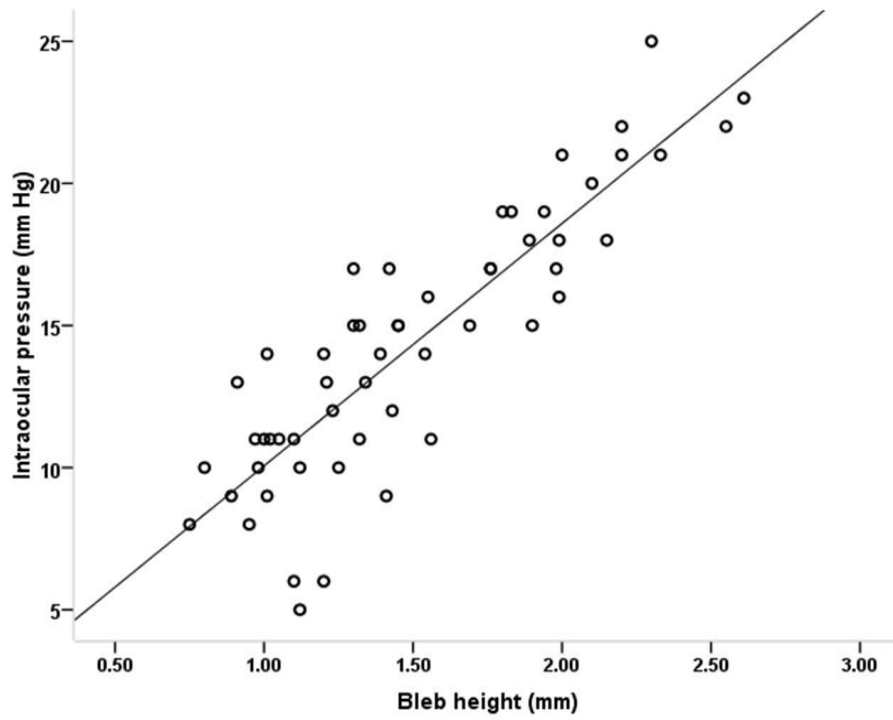


Figure 4. Correlation between bleb height measured by optical coherence tomography and intraocular pressure ($P < 0.001$, $r = 0.87$)

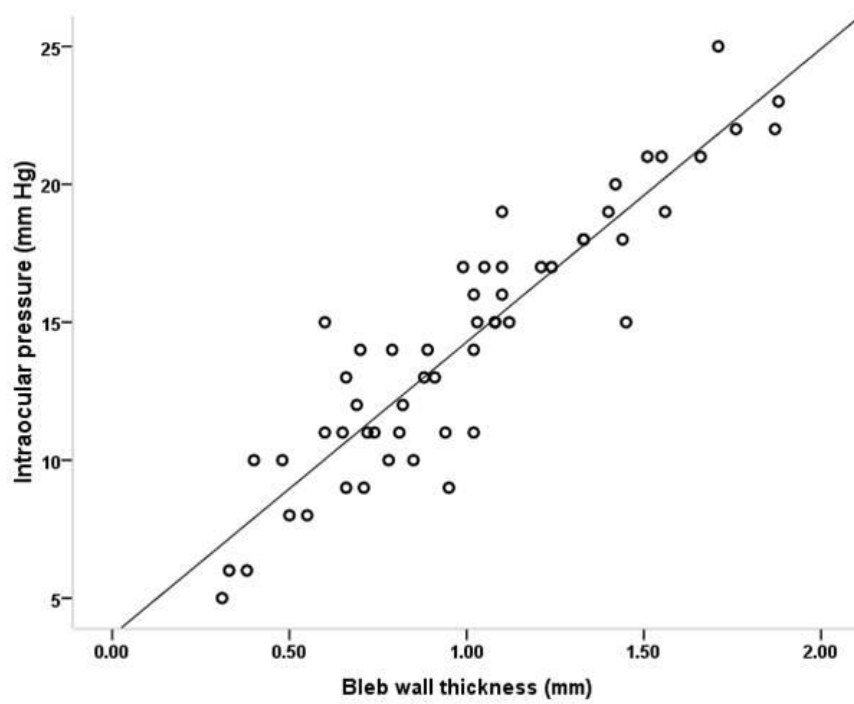


Figure 5. Correlation between bleb wall thickness measured by optical coherence tomography and intraocular pressure ($P < 0.001$, $r = 0.91$)

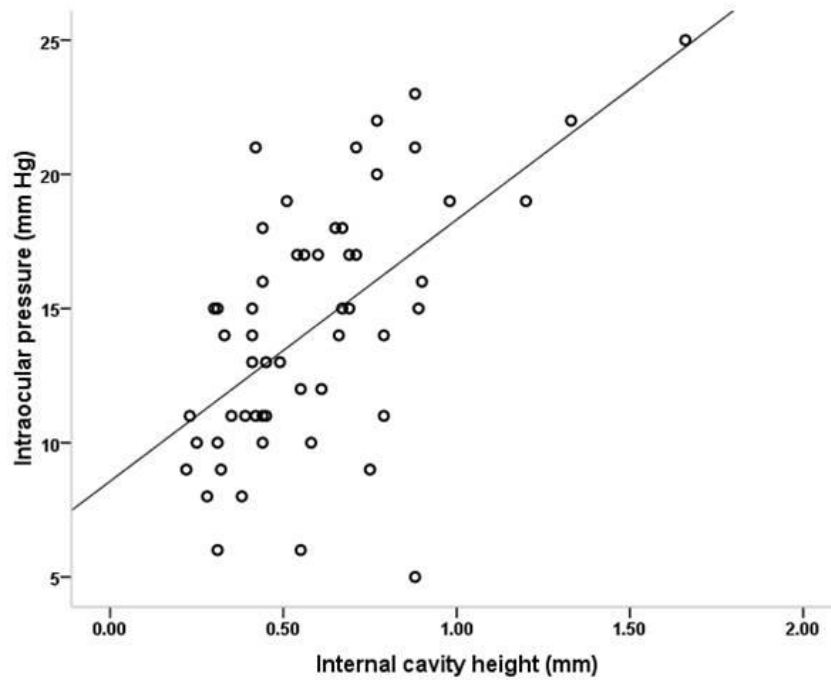


Figure 6. Correlation between internal cavity height measured by optical coherence tomography and intraocular pressure ($P < 0.001$, $r = 0.59$)

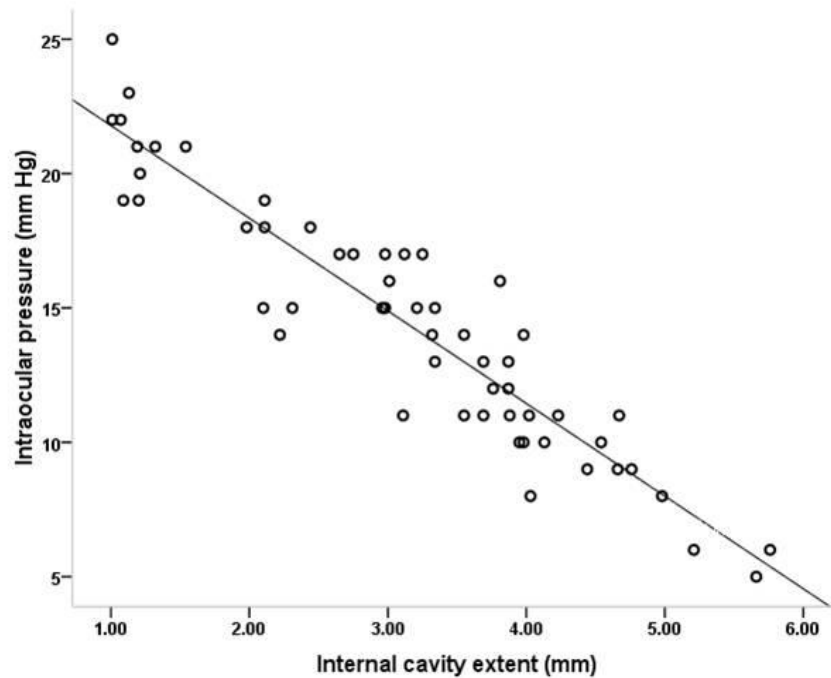


Figure 7. Correlation between internal cavity extent measured by optical coherence tomography and intraocular pressure ($P < 0.001$, $r = -0.94$)

Discussion

Recently, a new imaging method (AS-OCT) has been used for a more detailed morphologic evaluation of the bleb structure. It has been reported that AS-OCT can provide high quality images of the anterior segment structures including internal structures of the filtering blebs.⁷⁻¹⁴ Researchers have tried to find out certain internal bleb characteristics and criteria on AS-OCT scans and correlate them with clinical examination of filtering bleb, and also bleb functionality, mainly IOP.^{8,13}

In this study, we tried to find out further filtering bleb characteristics and criteria on AS-OCT scans, and also evaluate any correlation between these findings and objective clinical examination of filtering blebs on IBAGS and IOP. To the best of our knowledge, this is the first report on correlation between the AS-OCT findings of filtering blebs and objective evaluation of the filtering blebs (IBAGS).

We showed that there was a positive correlation between the bleb height, bleb wall thickness, internal cavity height, and high internal bleb reflectivity on AS-OCT and IOP. Positive association between the bleb wall thickness and also internal bleb reflectivity and higher IOPs seemed reasonable, but positive correlation between the bleb height and IOP might look strange. This can be justified based on the fact that in a post-filtering eye with a relatively high IOP, but with a still functional bleb, bleb height could be increased secondary to pushing effect of IOP. Since most of our patients were undergone trabeculectomy within the recent months (mean=9.46 months), some of our patients had encapsulated filtering blebs with higher bleb heights and thicker bleb walls. We believe that this should be considered as an important criterion in bleb evaluation on AS-OCT examination.

We also noted that there was a negative correlation between the posterior extension of the internal cavity and IOP. This shows that, in contrast with the bleb height, bleb extent is directly associated with the bleb functionality and lower IOPs.

There has also been a positive correlation between the bleb height at IBAGS and bleb reflectivity at AS-OCT. Moreover, we found that there was a positive correlation between the bleb vascularity at IBAGS and internal

reflectivity at AS-OCT. All these findings were in accordance with one's expectations and showed a high association between the objective grading of filtering blebs and AS-OCT findings.

In a study, Zhang et al concluded that AS-OCT resolution was significant and could well evaluate the bleb internal structure at any time after surgery. They found that functional blebs had a thickened wall or low internal reflectivity.¹²

Stefan and colleagues in 2003 reported that filtering blebs with some conjunctival subepithelial microcysts on AS-OCT showed much lower IOPs, and blebs with corkscrew vessels had higher IOPs.¹⁵ This is in accordance with our findings, since filtering blebs with conjunctival subepithelial microcysts show lower internal reflectivity.

Singh and colleagues in a study in 2007 observed that successful blebs in AS-OCT had thick walls, and unsuccessful blebs had thin walls and ostial occlusion.¹¹ These findings are in obvious contrast with our findings, and we believe that our findings are more correlated with clinical findings. Since discriminating between bleb wall and bleb internal structures on AS-OCT is not an easy task, the rationale behind the disagreements between our findings and theirs might have come from the precision in determining and discriminating between the bleb wall and bleb internal structures on AS-OCT scans, and ours might have been more precise. Further studies may be needed to clarify this debate.

Marco and coworkers in a study in 2008 concluded that a good correlation had been between AS-OCT findings and the clinical classification of bleb types; that, in turn, increased the ability of the clinicians on the proper decision making for the filtering bleb managements. In this study, they also reported that, compared with the failed one, successful blebs had a higher number, density, and total area of intraepithelial microcysts and a thinner stromal layer.⁹

Smith et al reported that increased bleb height in clinical evaluation of filtering blebs was significantly associated with low IOP, but there was not any association between the bleb vascularity, presence of microcysts, and extension of bleb and IOP.¹⁶

Tominaga showed that neither the extent of internal cavity nor the bleb height was significantly correlated with IOP. They reported that only bleb wall thickness was negatively correlated with IOP.⁸

Our study showed that there is a strong positive correlation between the IOP and bleb height and bleb wall thickness, but it could be due to a selection bias (encapsulated blebs). Furthermore, we found a strong negative correlation between IOP and bleb internal cavity extent. This is a parameter that could not be evaluated by clinical examination of a filtering bleb, and can only be obtained via AS-OCT.

Among the limitations of our study was inability to get slit-lamp photographs of the filtering blebs for IBAGS scoring to be compared with standard photographs. This could interfere with the clinical grading scores. Also, since getting accurate scans took some time, and needed patients' cooperation and patience, patient recruitment for this study

was not found to be an easy task.

Conclusion

In conclusion, AS-OCT could be considered as a useful tool for evaluating filtering bleb function, specially for examination of the internal structures of the filtering blebs. It can easily differentiate blebs which are still functional from scarred or failed blebs. Furthermore, AS-OCT findings are correlated with clinical findings of the filtering blebs and could help the clinicians on determining certain features and characteristics of the filtering blebs, and on decision making when and how to intervene for saving the functionality of blebs, specially needing bleb revision for encapsulated blebs.

The combined use of different techniques including slit-lamp examination and AS-OCT imaging may improve the clinician's ability in achieving significant information regarding the bleb morphology and functionality, and in correctly classifying the blebs types.

References

1. Cairns JE. Trabeculectomy. Preliminary report of a new method. *Am J Ophthalmol* 1968;66(4):673-9.
2. Quigley HA, Friedman DS, Hahn SR. Evaluation of practice patterns for the care of open-angle glaucoma compared with claims data: the Glaucoma Adherence and Persistency Study. *Ophthalmology* 2007;114(9):1599-606.
3. Migdal C, Hitchings R. The developing bleb: effect of topical antiprostaglandins on the outcome of glaucoma fistulising surgery. *Br J Ophthalmol* 1983;67(10):655-60.
4. Addicks EM, Quigley HA, Green WR, Robin AL. Histologic characteristic of filtering blebs in glaucomatous eyes. *Arch Ophthalmol* 1983;101(5):795-8.
5. Cantor LB, Mantravadi A, WuDunn D, et al. Morphologic classification of filtering blebs after glaucoma filtration surgery: the Indiana Bleb Appearance Grading Scale. *J Glaucoma* 2003;12(3):266-71.
6. Wells AP, Crowston JG, Marks J, et al. A pilot study of a system for grading of drainage blebs after glaucoma surgery. *J Glaucoma* 2004;13(6):454-60.
7. Singh M, Aung T, Friedman DS, et al. Anterior segment optical coherence tomography imaging of trabeculectomy blebs before and after laser suture lysis. *Am J Ophthalmol* 2007;143(5):873-5.
8. Tominaga A, Miki A, Yamazaki Y, et al. The Assessment of the filtering bleb function with anterior segment optical coherence tomography. *J Glaucoma* 2010;19(8):551-5.
9. Ciancaglini M, Carpineto P, Agnifili L, et al. Filtering bleb functionality: a clinical anterior segment optical coherence tomography and in vivo confocal microscopy study. *J Glaucoma* 2008;17(4):308-17.
10. Leung CK, Yick DW, Kwong YY, et al. Analysis of bleb morphology after trabeculectomy with the Visante anterior segment optical coherence tomography. *Br J Ophthalmol* 2007;91(3):340-4.
11. Singh M, Chew PT, Friedman DS, et al. Imaging of trabeculectomy blebs using anterior segment optical coherence tomography. *Ophthalmology* 2007;114(1):47-53.
12. Zhang Y, Wu Q, Zhang M, et al. Evaluating subconjunctival bleb function after trabeculectomy using slit-lamp optical coherence tomography and ultrasound biomicroscopy. *Chin Med J (Engl)* 2008;121(14):1274-9.
13. Pfenninger L, Schneider F, Funk J. Internal reflectivity of filtering blebs versus intraocular pressure in patients with recent trabeculectomy. *Invest Ophthalmol Vis Sci* 2011;52(5):2450-5.
14. Jancevski M, Foster CS. Anterior segment optical coherence tomography. *Semin Ophthalmol* 2010;25(5-6):317-23.
15. Sacu S, Rainer G, Findl O, et al. Correlation between the early morphological appearance of filtering blebs and outcome of trabeculectomy with mitomycin C. *J Glaucoma* 2003;12(5):430-5.
16. Smith M, Chipman ML, Trope GE, Buys YM. Correlation between the Indiana bleb appearance grading scale and intraocular pressure after phacotrabeculectomy. *J Glaucoma* 2009;18(3):217-9.