

model eye and HOAs and IOL position measurements were repeated. In addition, there was no significant difference in 3rd, 4th, and total HOAs root mean square except spherical aberration in +20.00 D IOLs. We therefore considered IOL position to have little influence on HOAs except spherical aberration. If the tilt and decentration of the IOL is significant, IOL positions influence HOAs in our model eye. We changed our model eye's IOL folder for displacement of IOL. We are measuring HOAs of the model eye to determine the effects of IOL displacement.—*Futoshi Taketani, MD*

## REFERENCE

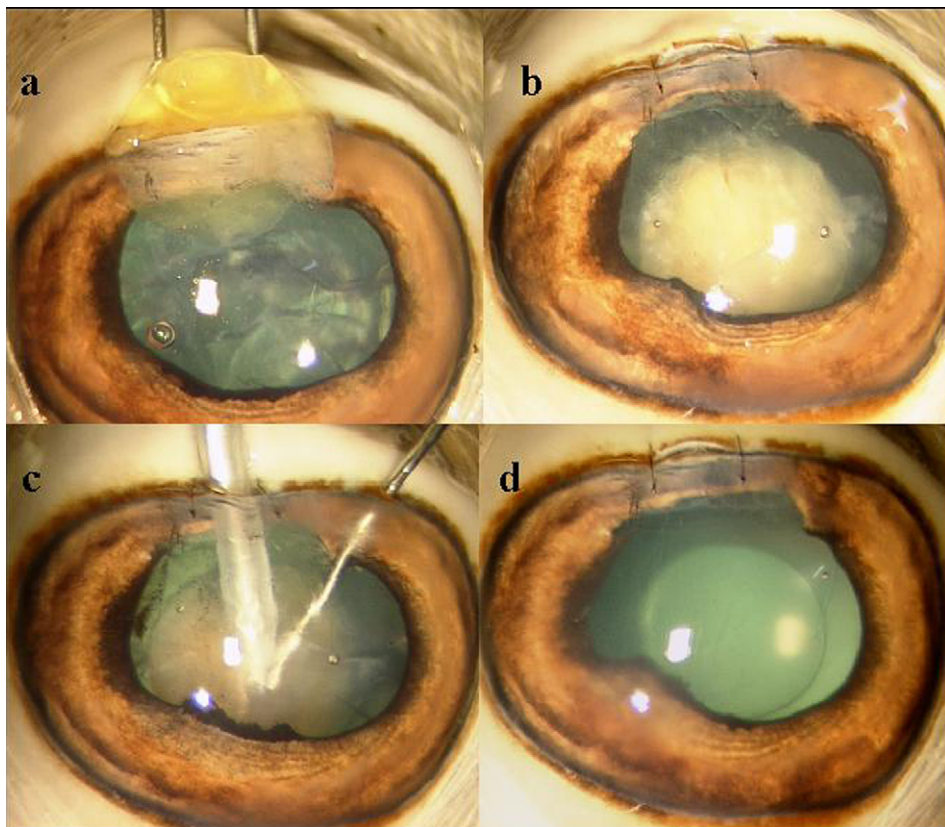
1. Taketani F, Matsuura T, Yukawa E, Hara Y. Influence of intraocular lens tilt and decentration on wavefront aberrations. *J Cataract Refract Surg* 2004; 30:2158–2162

## Goat eye with human nucleus for phacoemulsification training

We read with interest the article by Mohammadi et al.<sup>1</sup> Ophthalmology training involves practicing surgery in animal,<sup>1–3</sup> cadaver,<sup>4</sup> or artificial<sup>5</sup> eyes. Because nucleotomy forms the major part of phacoemulsification, simulation of the human nucleus has been

attempted.<sup>1,4</sup> We have removed human lens nuclei from patients who had extracapsular cataract extraction (ECCE) and implanted them in enucleated goat eyes for phacoemulsification training. The nucleus was delivered carefully, stored in Ringer lactate at 4°C, and transported to an experimental operating room. A side-port incision was made and an ophthalmic viscosurgical device (OVD) injected into the anterior chamber. A corneal tunnel incision 3.2 mm was made and capsulorhexis performed.

Phacoemulsification of the central core of the goat's nucleus was done, leaving a cushion of lens material that created space for the human nucleus that was filled with OVD. The corneal tunnel incision width was 1.0 mm larger than the diameter of the human nucleus, which was placed over the lens vectis and implanted in the space created in the goat lens in a manner exactly opposite the nucleus delivery during ECCE (Figure 1, A). The corneal tunnel was sutured except for a 3.0 mm area (Figure 1, B) from which phacoemulsification of the human nucleus inside the goat eye was done. The chopper was inserted through the previously created side port (Figure 1, C). The goat lens material was aspirated using an irrigation/aspiration handpiece. The globe was refilled with OVD and a foldable intraocular lens implanted (Figure 1, D).



**Figure 1.** A: Implantation of the human nucleus obtained after ECCE in goat's eye using wire vectis. B: Human nucleus in goat's capsular bag; 3.0 mm corneal tunnel incision is left unsutured. C: Nuclear emulsification of human nucleus in goat's eye. D: Foldable intraocular lens implanted in the bag.

This model was used in 11 goat eyes with the divide-and-conquer (5 nuclei, grade 4 hardness), stop-and-chop (4 nuclei, grade 3 hardness), and chip-and-flip (2 nuclei, grade 2 hardness) phacoemulsification techniques. The use of human nuclei aids practicing and perceiving the real-time hardness that the novice surgeon may encounter in various clinical situations.

**Prashant Bhartiya, MD, DNB, FRCS**  
**Manjunatha N.P., MD**  
**Namrata Sharma, MD**  
*New Delhi, India*

## REFERENCES

1. Mohammadi SF, Mazouri A, Jabbarvand M, Rahman-A N, Mohammadi A. Sheep practice eye for ophthalmic surgery training in skills laboratory. *J Cataract Refract Surg* 2011; 37:987–991
2. Sudan R, Titiyal JS, Sethi HS, Rai HK. Animal model for teaching phacoemulsification. *J Cataract Refract Surg* 2002; 28:4–5
3. Van Vreeswijk, Pameyer JH. Inducing cataract in postmortem pig eyes for cataract surgery training purposes. *J Cataract Refract Surg* 1998; 24:17–18
4. Borirak-chanyavat S, Lindquist TD, Kaplan HJ. A cadaveric eye model for practicing anterior and posterior segment surgeries. *Ophthalmology* 1995; 102:1932–1935
5. Maloney WF, Hall D, Parkinson DB. Synthetic cataract teaching system for phacoemulsification. *J Cataract Refract Surg* 1988; 14:218–221

**Reply:** The idea of inserting a human cataract into an animal eye to create a phacoemulsification model was first reported by Tolentino and Liu in 1975.<sup>1</sup> However, ophthalmology skill laboratory development now involves wider practices; ie, efficient methods for animal eye harvest, fixation,<sup>2</sup> and preparation. Cataract induction in animal eyes is an example of such “preparations.” Microwave energy and chemical treatment have been used, human cataracts have been implanted,<sup>3</sup> and cooked chestnuts have been inserted<sup>4</sup> to prepare the animal eye for phacoemulsification.

Practicing in a real human cataract provides the opportunity to experience real tissue interaction,<sup>3</sup> and Bhartiya et al. nicely applied several endocapsular phacoemulsification techniques on the human nucleus in a goat eye. However, this report is a reminder of Kayıkçıoğlu et al.'s study in 2004<sup>5</sup> in which they practiced phacofracture and phacoemulsification on the human lens in sheep eyes. They even used a single sheep eye for more than 1 human cataract emulsification.

Bhartiya et al. recognize that nucleotomy is the major part of phacoemulsification. This might be true, but surgical practice for cataract is much more sophisticated than emulsification alone. For a beginning surgeon, hand-motor coordination, foot pedal control,

microscope facility, phaco machine orientation, and handpiece handling are the essential initial steps; keratotomy (for a sutureless procedure and prolapse-free incision), use of capsule dye and OVD, anterior capsulorhexis, hydrodissection, and stromal hydration are as important as nucleotomy. Bimanual exercise, phacodynamic manipulation, sculpting, cracking, irrigation/aspiration, and intraocular lens handling and implantation (with forceps or injector) can be practiced or attempted in animal eyes without enhancements. Even uncommon situations such as posterior capsule rupture can be induced and anterior vitrectomy practiced. Artificial eyes are comparatively more expensive, but they can be reserved for learning specific skills such as chopping.

We believe that the objective of animal model use is to streamline surgical teaching and learning, make the initial challenges manageable, and address the ethical dilemma rather than to provide full imitation of surgical experience. For instance, the goat lens is almost 8.0 mm thick<sup>6</sup> and full aspiration of its nuclear material is time consuming and is not similar to aspiration of the human lens. Bhartiya et al. did several preparatory tasks: They “harvested” human cataractous nuclei, preserved them, inserted them, and added sutures around the entry to prepare the model for practice. Such tasks might be the reasons that the enhancements are not popularized, and the method may face nucleus shortage in centers in which phacoemulsification is the standard procedure.<sup>3</sup> It should also be noted that lens nucleus is a human tissue and precautions in tissue handling and disposal have to be adopted.

Round-the-clock on-demand availability (and preserving corneal clarity) is the other challenge with animal eye practice. We have recently investigated this and are in the process of reporting the results. —S. Farzad Mohammadi, MD, Arash Mazouri, MD, Mahmoud Jabbarvand, MD, Nazanin Rahman-A, MD, Aeen Mohammadi, MD, MPH

## REFERENCES

1. Tolentino FI, Liu HS. A laboratory animal model for phacoemulsification practice. *Am J Ophthalmol* 1975; 80:545–546
2. Mohammadi SF, Mazouri A, Rahman-A N, Jabbarvand M, Peyman GA. Globe-fixation system for animal eye practice. *J Cataract Refract Surg* 2011; 37:4–7
3. Henderson BA, Grimes KJ, Fintelmann RE, Oetting TA. Stepwise approach to establishing an ophthalmology wet laboratory. *J Cataract Refract Surg* 2009; 35:1121–1128
4. Mekada A, Nakajima J, Nakamura J, Hirata H, Kishi T, Kani K. Cataract surgery training using pig eyes filled with chestnuts of various hardness. *J Cataract Refract Surg* 1999; 25:622–625
5. Kayıkçıoğlu Ö, Eğrilmez S, Emre S, Erakgün T. Human cataractous lens nucleus implanted in a sheep eye lens as a model for phacoemulsification training. *J Cataract Refract Surg* 2004; 30:555–557