



Middle East Afr J Ophthalmol. 2015 Jul-Sep; 22(3): 352–355.

PMCID: PMC4502181

doi: [10.4103/0974-9233.159761](https://doi.org/10.4103/0974-9233.159761)

## Hinged Capsulotomy – Does it Decrease Floaters After Yttrium Aluminum Garnet Laser Capsulotomy?

[Fatemeh Alipour](#), [Mahmoud Jabbarvand](#), [Hesam Hashemian](#), [Simindokht Hosseini](#), and [Mehdi Khodaparast](#)

Department of Ophthalmology, Eye Research Center, Farabi Eye Hospital, Tehran University of Medical Sciences, Tehran, Iran

**Corresponding Author:** Dr. Hesam Hashemian, Eye Research Center, Farabi Eye Hospital, Tehran University of Medical Sciences, Ghazvin Sq., Tehran, Iran. E-mail: [h-hashemian@tums.ac.ir](mailto:h-hashemian@tums.ac.ir)

**Copyright** : © Middle East African Journal of Ophthalmology

This is an open-access article distributed under the terms of the Creative Commons Attribution-Noncommercial-Share Alike 3.0 Unported, which permits unrestricted use, distribution, and reproduction in any medium, provided the original work is properly cited.

### Abstract

#### Objectives:

The objective was to compare conventional circular yttrium aluminum garnet (YAG) laser capsulotomy with hinged capsulotomy to manage posterior capsular opacification (PCO).

#### Materials and Methods:

This prospective, randomized clinical trial enrolled pseudophakic patients with visually significant posterior capsule opacification. Patients were randomized to undergo posterior YAG laser capsulotomy with either conventional circular technique or a new technique with an inferior hinge. At 1-month postoperatively, patients were asked if they had any annoying floaters and the responses were compared between groups.  $P < 0.05$  was considered statistically significant.

#### Results:

A total of 83 patients were enrolled. Forty-three patients underwent hinged posterior YAG capsulotomy and 40 patients underwent routine circular capsulotomy. At 1-month postoperatively, there was a statistically significant decrease in annoying floaters in the group that underwent circular capsulotomy ( $P = 0.02$ ). There was no statistically significant association in the total energy delivered ( $P = 0.4$ ) or the number of spots ( $P = 0.2$ ) and patient perception of annoying floaters.

#### Conclusion:

Hinged YAG capsulotomy was effective at decreasing the rate of floaters in patients with PCO.

**Keywords:** Floater, Hinged, Neodymium-doped Yttrium Aluminum Garnet Laser, Posterior Capsulotomy

### INTRODUCTION

Posterior capsular opacification (PCO) is one of the most common postoperative complications of cataract surgery. The incidence of PCO ranges from 25% to 50% depending on the duration of follow-up in older literature.<sup>1,2,3</sup> However, advances in intraocular lens (IOL) design<sup>4</sup> and materials<sup>5,6</sup> have resulted in a significant reduction of the incidence of PCO over time. A recent study reported the rate of PCO was 16% over a 7 years period.<sup>7</sup>

Neodymium-doped yttrium aluminum garnet (Nd-YAG) laser capsulotomy has been the standard treatment for PCO. However, in cases with dense fibrotic PCO or in young poorly cooperative children, surgical interventions can be performed. There are some complications of Nd-YAG laser capsulotomy, including,

increased intraocular pressure (IOP), anterior uveitis, hyphema, IOL pitting, presence of vitreous in the anterior chamber and macular edema, and retinal break and detachment.<sup>8</sup> Some complications, such as floaters are not devastating, but are annoying to the patient for a long period of time. The free-floating remnants of the posterior capsule in the synergetic vitreous of elderly patients are presumably the cause of these annoying floaters.

There are a number of capsulotomy techniques that have been introduced, each with its advantages and disadvantages. The most common technique is circular capsulotomy. Another technique, cross-shaped capsulotomy, carries a greater risk of damage to the center of the IOL. In 1999, Zeki suggested an inverted U-shaped capsulotomy.<sup>8</sup> We proposed the concept of preventing the capsule from free floating by performing an incomplete capsulotomy. Currently, there are no studies in the literature to confirm this theory of a hinged (inverted U-shaped) capsulotomy. Hence, the current study evaluates the potential advantages of this technique.

## MATERIALS AND METHODS

---

Patients with decreased vision for more than 4 months after cataract surgery who had a significant posterior capsular opacity and no significant ocular pathologies were enrolled. All patients underwent a thorough ophthalmic examination including, subjective refraction, slit lamp examination of the cornea and anterior chamber, and dilated fundus examination. Inclusion criteria were a decrease of 2 or more lines of best-corrected visual acuity (BCVA) attributable to PCO based on evaluation by an experienced ophthalmologist. PCO grading was performed according to evaluation of PCO (EPCO) system as follows: Grade 1 denoted minimum posterior capsule wrinkling; Grade 2 denoted mild honeycomb PCO; Grade 3 denoted classic Elschnig pearls and; Grade 4 denoted severe opacity with a darkening effect.<sup>9</sup> Grading was performed based on clinical judgment during slit-lamp examination. Cases with any other probable cause of decreased vision were excluded. Patients with any other abnormal findings such as diabetic retinopathy, glaucoma, corneal opacity or corneal decompensation after cataract surgery were excluded from this study.

Informed consent was obtained from all participants. The ethics committee and Institutional Review Board of Tehran University of Medical Sciences approved this study. Patients who met the inclusion criteria were asked to sign an informed consent form after a thorough explanation of the risks and benefits of the procedure and alternate options for treatment. Patients were randomized to undergo either a hinged capsulotomy (hinged group) or conventional circular capsulotomy (conventional group) [Figure 1]. Patients were masked to the type of capsulotomy they received until the end of the study. Data were collected on patient demographics and characteristics of the procedure such as the number of spots, delivered energy, and the size of the capsulotomy.

In both groups, tropicamide 1% (Sina Darou, Tehran, Iran) was administered 20 min before the procedure. The same ophthalmologist performed Nd-YAG capsulotomy with a YAG laser (Carl Zeiss, Jena, Germany) for all cases. In the hinged group, an incomplete circle maintaining an inferior 90° hinge was performed. In the hinged group, the attachment of the capsule was maintained inferiorly, with the attachment acting as a hinge for the remnant of the capsule. In both groups, the lowest energy setting was selected that was effective at disrupting the PCO.

Postoperatively, topical betamethasone and timolol were prescribed to all patients for 1-week. IOP was checked 2 h after the procedure and cases with increased IOP were treated with antiglaucoma medication as warranted. One-month postoperatively, a complete ophthalmic examination was performed including measurement of corrected and uncorrected vision, and measurement of the size of the opening on the posterior capsule using a slit lamp gauge. Each patient filled out a simple questionnaire about floaters.

Preoperative and postoperative data were compared using the Pearson Chi-square and Student's *t*-test. Statistical analysis was performed with SPSS software (version 15.0; IBM Corp., New York, NY, USA). A *P* < 0.05 was considered statistically significant. Data are reported as the mean ± standard deviation.

## RESULTS

---

Eighty-six eyes of 86 patients were included in the study of which three were excluded due to missed follow-up visits. There were 45 (54.2%) right eyes and 38 left eyes. Mean patient age was 63.2 ± 6.6 years

(range, 49 to 79 years). The hinged group was comprised of 43 eyes, and there 40 eyes in the conventional group. All eyes had undergone phacoemulsification with IOL implantation. Mean duration between cataract surgery and YAG capsulotomy was  $19.8 \pm 11.6$  months (range, 4–72 months).

Based on the EPCO grading system; 15 patients (18.1%) had Grade 1 PCO; 31 patients (37.3%) had Grade 2 PCO; 22 patients (26.5%) had Grade 3 PCO and; 15 patients (18.1%) had Grade 4 PCO. There was no significant difference in the distribution of the different grades of PCO between groups ( $P > 0.05$ ) [Table 1].

The total amount of energy delivered to the eye, number of spots, and final BCVA 1-month after capsulotomy were not statistically significantly different between groups ( $P > 0.05$  all between-group comparisons). There was no association between the PCO grade and the energy required or the number of spots in either group. There was no significant association between the degree of PCO and the interval between cataract surgery and the laser procedure ( $P = 0.4$ ). The size of the opening in the posterior capsule was not significantly different between groups ( $P = 0.4$ ).

All cases in the hinged group had a clear visual axis at follow-up. Detailed comparative data of the two subgroups are presented in Table 2. During follow-up, shrinkage of the capsule occurred and the capsular remnant became immobile in the inferior region of the capsulotomy.<sup>8</sup>

Patients were asked about annoying floaters at the 1-month follow-up visit. Comparative analysis between groups revealed a statistically significant difference between the two subgroups; 36% of all cases reported annoying floaters. There were 50% of the patients in the conventional group and 24% of the patients in the hinged group, who complained of annoying floaters 1-month after the procedure. This difference was statistically significant lower for the hinged group ( $P = 0.02$ ). The likelihood ratio was 6.51 for the presence of annoying floaters in patients who underwent conventional capsulotomy ( $P = 0.011$ ).

## DISCUSSION

---

In the current study, hinged (inverted U-shaped) capsulotomy statistically significantly decreased the incidence of floaters compared to conventional circular capsulotomy. This concurs with the basic concept behind the hinged technique,<sup>8</sup> which was as effective as the circular method in clearing the visual axis and improving BCVA in our study.

Although we assumed that the hinged technique would result in decreased total energy delivered to the eye, we could not show a significant difference in total energy levels or spot numbers despite a small trend in favor of the hinged group. These variables should be evaluated in a study with a larger sample size. Future studies should incorporate an objective system for grading the visual significance of the PCO<sup>9</sup> and evaluate visual acuity, contrast sensitivity and glare. In addition, stratifying the energy levels based on the PCO grading may determine if any association exists.

Yttrium aluminium garnet laser capsulotomy is the standard method of removing PCO. Considering the remarkable prevalence of PCO<sup>10</sup> despite improvements in IOL materials and surgical techniques, surgeons should consider safer methods of capsulotomy. Hinged technique seems to be ideal for most cases of PCO both by avoiding targeting the center of the IOL and lowering the rate of floaters.

## Footnotes

---

**Source of Support:** Nil

**Conflict of Interest:** None declared.

## REFERENCES

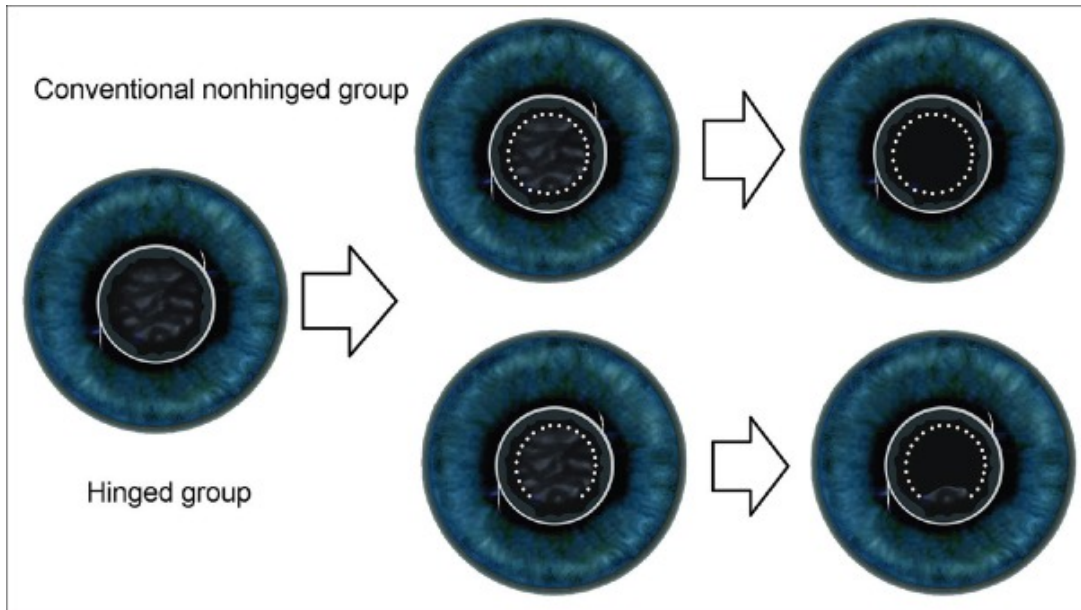
---

1. Apple DJ. Influence of intraocular lens material and design on postoperative intracapsular cellular reactivity. *Trans Am Ophthalmol Soc.* 2000;98:257–83. [PMCID: PMC1298231] [PubMed: 11190028]
2. Werner L, Apple DJ, Pandey SK. Postoperative proliferation of anterior and equatorial lens epithelial cells: A comparison between various foldable IOL designs. In: Buratto L, Osher R, Masket S, editors. *Cataract Surgery in Complicated Cases.* Thorofare, NJ: Slack Inc.; 2000.

3. Apple DJ, Solomon KD, Tetz MR, Assia EI, Holland EY, Legler UF, et al. Posterior capsule opacification. *Surv Ophthalmol.* 1992;37:73–116. [PubMed: 1455302]
4. Kohnen T, Fabian E, Gerl R, Hunold W, Hütz W, Strobel J, et al. Optic edge design as long-term factor for posterior capsular opacification rates. *Ophthalmology.* 2008;115:1308–14. 1314.e1–3. [PubMed: 18321585]
5. Findl O, Menapace R, Sacu S, Buehl W, Rainer G. Effect of optic material on posterior capsule opacification in intraocular lenses with sharp-edge optics: Randomized clinical trial. *Ophthalmology.* 2005;112:67–72. [PubMed: 15629822]
6. Vasavada AR, Raj SM, Shah A, Shah G, Vasavada V, Vasavada V. Comparison of posterior capsule opacification with hydrophobic acrylic and hydrophilic acrylic intraocular lenses. *J Cataract Refract Surg.* 2011;37:1050–9. [PubMed: 21596247]
7. Østern AE, Saethre M, Sandvik G, Råen M, Drolsum L. Posterior capsular opacification in patients with pseudoexfoliation syndrome: A long-term perspective. *Acta Ophthalmol.* 2013;91:231–5. [PubMed: 22405320]
8. Zeki SM. Inverted U' strategy for short pulsed laser posterior capsulotomy. *Acta Ophthalmol Scand.* 1999;77:575–7. [PubMed: 10551304]
9. Nixon DR, Woodcock MG. Pattern of posterior capsule opacification models 2 years postoperatively with 2 single-piece acrylic intraocular lenses. *J Cataract Refract Surg.* 2010;36:929–34. [PubMed: 20494763]
10. Apple DJ, Peng Q, Visessook N, Werner L, Pandey SK, Escobar-Gomez M, et al. Eradication of posterior capsule opacification: Documentation of a marked decrease in Nd: YAG laser posterior capsulotomy rates noted in an analysis of 5416 pseudophakic human eyes obtained postmortem. *Ophthalmology.* 2001;108:505–18. [PubMed: 11237905]

## Figures and Tables

---

**Figure 1**

Schematic of the process of capsulotomy in each group. The dotted white line indicates the capsulotomy border

**Table 1**

	Grade 1	Grade 2	Grade 3	Grade 4
Hinged	9	16	12	6
Non-hinged	6	15	10	9

Grading is according to EPCO system.  $\chi^2=1.1$ ,  $df=3$ ,  $P=0.3$ . EPCO: Evaluation of posterior capsule opacification

Distribution of different grades of PCO in the two groups that underwent capsulotomy

**Table 2**

	Total	Hinged	Circular	P
Number of cases	83	43	40	-
Mean number of laser spots	22.2±7.5	21.4±6.8	23.1±8.1	0.20
Mean energy (mJ)	54.8±19.7	53.1±17.8	56.7±21.7	0.40
Mean diameter of capsulotomy after a month (mm)	4.6±0.5	4.5±0.5	4.6±0.5	0.70
BCVA a month after capsulotomy (logMAR)	0.05±0.05	0.06±0.05	0.04±0.04	0.11
Floater (%)	36	24	50	0.02

*P*<0.05 was statistically significant. BCVA: Best corrected visual acuity

### Comparative data between the groups of hinged and circular capsulotomy

Articles from Middle East African Journal of Ophthalmology are provided here courtesy of **Wolters Kluwer -- Medknow Publications**