Intrastromal lamellar keratoplasty in patients with pellucid marginal degeneration

Mahmoud Jabbarvand, MD, Hesam Hashemian, MD, Mehdi Khodaparast, MD, Narges Hassanpour, MD, MPH, Masoumeh Mohebbi, MD

We describe a new method (intrastromal lamellar keratoplasty) to treat patients with pellucid marginal degeneration (PMD). After a pocket is created along the marked margins of the thinned inferior cornea with Melles dissectors, a crescent of the same size is marked on the donor cornea. The epithelial and endothelial layers are removed, and the donor tissue is cut in a crescentic shape in the size of the marked corneal pocket. The donor crescentic stroma is then inserted into the stromal pocket. The technique was performed in 10 eyes of 10 patients with PMD. The uncorrected and corrected distance visual acuities had significantly improved after 6 months. The cylinder was significantly reduced after 1 month and this was maintained up to 3 months of follow-up. Intrastromal lamellar keratoplasty appeared to be effective in the treatment of PMD.

Financial Disclosure: No author has a financial or proprietary interest in any material or method mentioned.

J Cataract Refract Surg 2015; 41:2–8 © 2015 ASCRS and ESCRS

Online Video

Pellucid marginal degeneration (PMD) is a rare idiopathic noninflammatory bilateral corneal ectasia, which is characterized by inferior crescent-shaped thinning of the corneal stroma (usually between 4 o'clock and 8 o'clock).[1] Several surgical therapies have been suggested for patients who cannot achieve an acceptable corrected distance visual acuity (CDVA) or tolerate nonsurgical therapies such as glasses, large-diameter rigid gas-permeable (RGP) contact lenses, and scleral contact lenses.[1,2]

Standard penetrating keratoplasty (PKP) may be associated with poor visual outcomes because of the proximity of the thinnest ectatic point to the limbus. Therefore, various surgeries have been performed for this disease, including large-diameter grafts, tuck-in lamellar keratoplasty, lamellar crescentic corneal wedge resection, lamellar crescentic keratoplasty, conductive thermokeratoplasty, epikeratoplasty, simultaneous central PKP and inferior peripheral lamellar keratoplasty, deep anterior lamellar keratoplasty (DALK), and intrastromal corneal ring segments (ICRS). Each of these procedures may have limitations and side effects, such as increased graft rejection risk and corneal vascularization in large grafts, poor visual outcomes with conductive thermokeratoplasty and epikeratoplasty, and high astigmatism after lamellar crescentic keratoplasty.[1–8]

We describe a new procedure in which a pocket is created along the marked margins of inferior thinning and a crescent of donor stroma is inserted into the pocket to reinforce the thin part of the diseased cornea.

SURGICAL TECHNIQUE

The surgical technique is shown in detail in Figure 1 and in Video 1 (available at: http://jcrsjournal.org). After the diseased cornea is carefully marked, guided

Submitted: February 6, 2014.
Final revision submitted: July 17, 2014.
Accepted: July 18, 2014.

From the Ophthalmology Research Center, Farabi Eye Hospital, Tehran University of Medical Sciences, Tehran, Iran.

Presented as a video presentation at the ASCRS Symposium on Cataract, IOL and Refractive Surgery, Chicago, Illinois, USA, April 2012.

Corresponding author: Hesam Hashemian, MD, Eye Research Center, Farabi Eye Hospital, South Kargar Street, Tehran, Iran. E-mail: h-hashemian@tums.ac.ir.

Published by Elsevier Inc.
http://dx.doi.org/10.1016/j.jcrs.2014.11.030
0886-3350

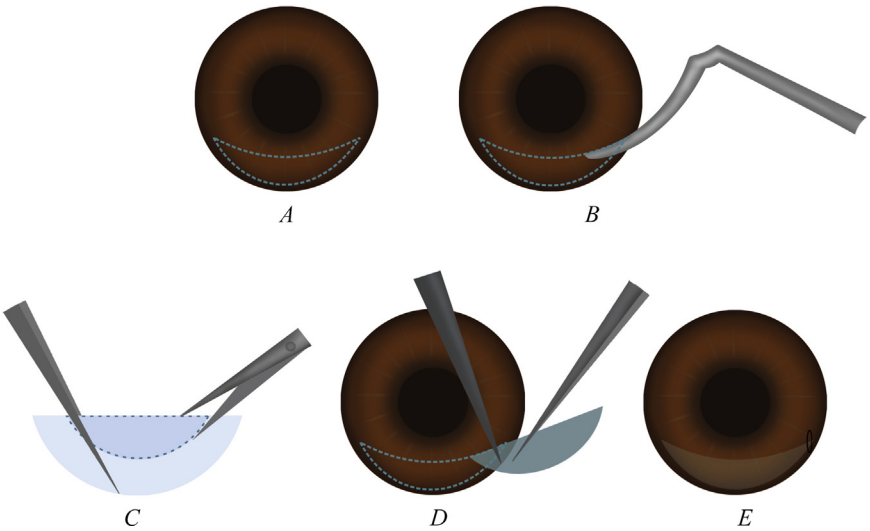

Figure 1. Intrastromal lamellar keratoplasty technique: *A*: Marking of thin part of the diseased cornea guided by corneal topography map in the shape of a crescent. *B*: Creation of a stromal pocket through the marked margins of inferior thinning with Melles dissectors. *C*: Following removal of the epithelium and endothelium layers, the donor corneal stroma is snipped in a crescent shape the same size as marked corneal pocket. *D*: Donor crescent shape corneal stroma is inserted gently into the pocket. *E*: Radial incision suturing.

by corneal topography maps in the shape of a crescent, a 2.0 mm long radial incision with a depth of 200 µm is placed off the temporal limbus by a diamond knife. Then a stromal pocket is created through the marked margins of the inferior thinning using Melles dissectors. The corneal stroma is carefully dissected to a depth of approximately 50%, avoiding perforation of Descemet membrane while dissecting the thinnest part of the cornea.

After the epithelial and endothelial layers are removed, the donor corneal stroma is cut in a crescent shape in the same size as the marked corneal pocket. The donor crescent-shaped corneal stroma is then gently inserted into the pocket. The final step is radial incision suturing. Unlike crescentic lamellar keratoplasty, which is done for PMD, intrastromal lamellar keratoplasty does not have to use multiple sutures to secure the crescentic lamellar graft to the cornea because of the creation of the pocket.

Results

Surgery was performed in 10 eyes of 10 patients with PMD (Figures 2 to 5). The diagnosis of PMD was made according to slitlamp examination (ectasia above the area of maximum thinning in the inferior cornea), corneal topography (butterfly keratometry pattern, very steep peripheral inferior cornea, high

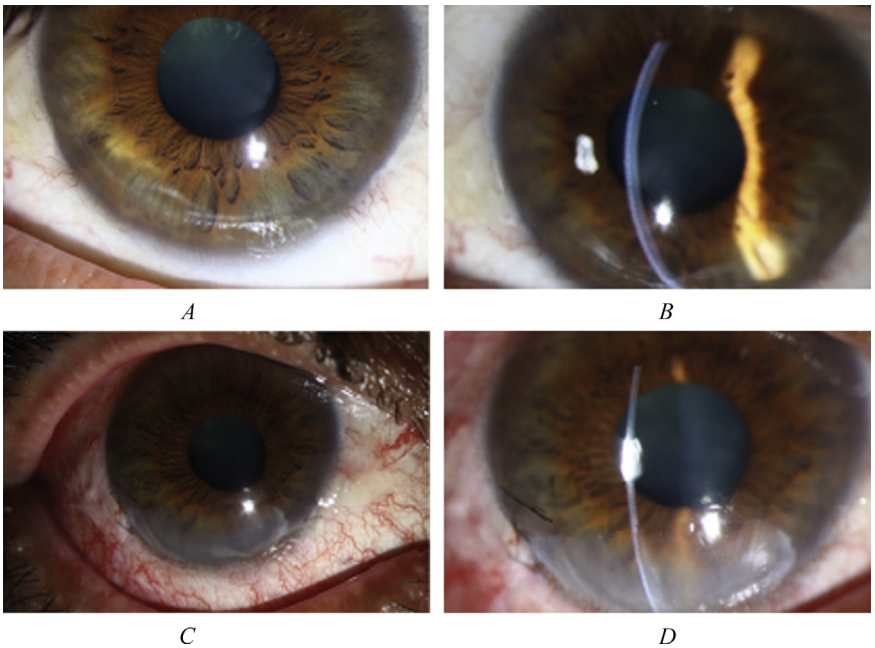

Figure 2. Slitlamp photograph of a patient with PMD before (*A* and *B*) and 3 months after (*C* and *D*) intrastromal lamellar keratoplasty.

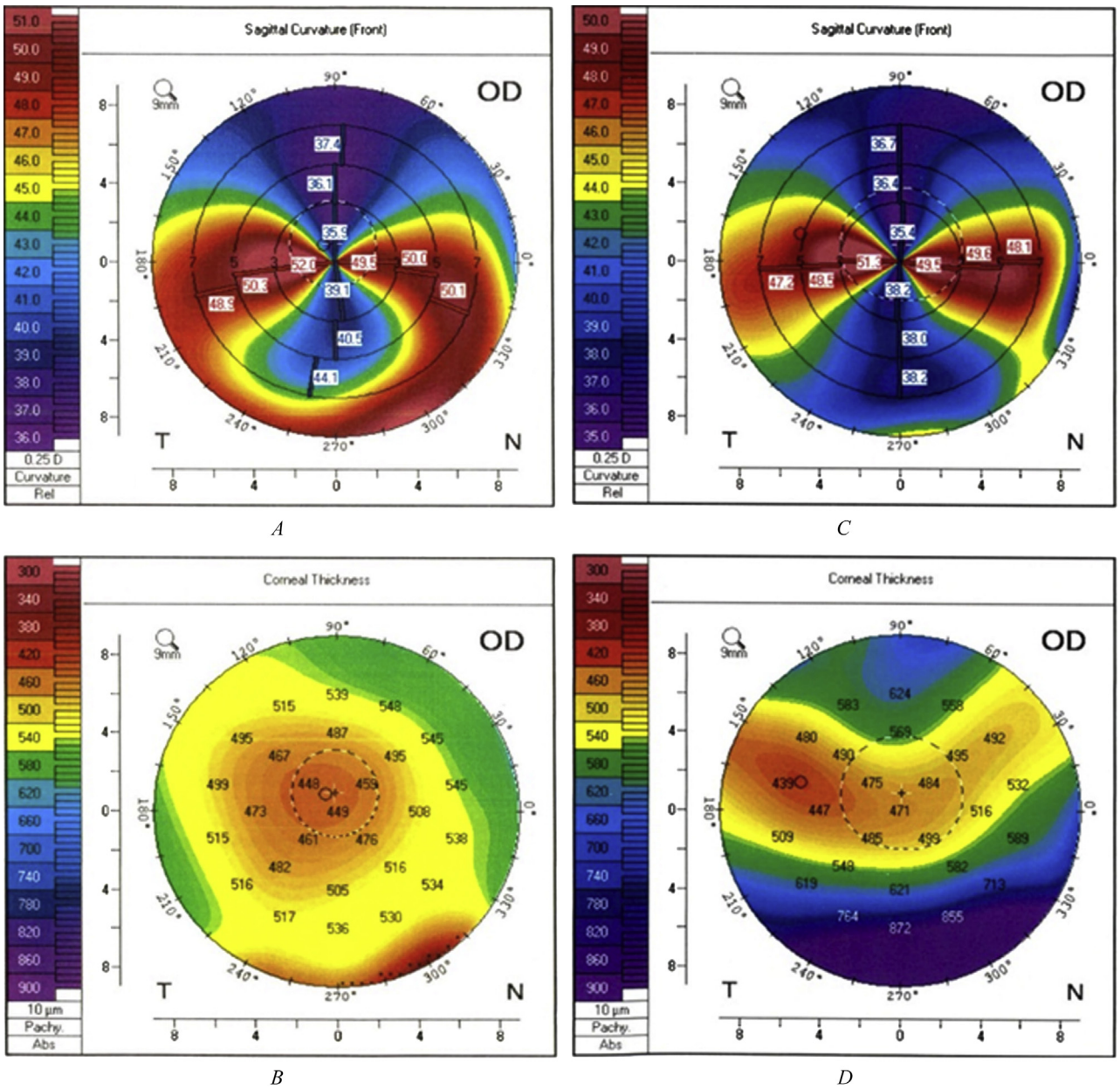

Figure 3. Preoperative (*A* and *C*) and 3 months postoperative (*B* and *D*) keratometric and pachymetry maps of a patient with pellucid marginal degeneration having intrastromal lamellar keratoplasty. Preoperative keratometry was 52.0 and 49.5 diopters (D) in the steep meridian and 35.9 and 39.1 D in the flat meridian. Postoperative keratometry was 51.3 and 49.5 D in the steep meridian and 35.4 and 38.2 D in the flat meridian. There was no clinically significant change in corneal astigmatism in this case.

keratometric powers radiating from the center to the inferior oblique meridians), and refractive findings (against-the-rule astigmatism with loss of CDVA). Only patients who wore glasses and were contact lens intolerant were included. All patients gave informed consent.

Preoperative and postoperative uncorrected distance visual acuity (UDVA) and CDVA, rotating Scheimpflug imaging (Pentacam), and refraction were assessed preoperatively and 1 month, 3 months, 6 months, and 1 year after the procedure (Table 1). The UDVA and CDVA had significantly improved 6 months after the surgery compared with their preoperative values. The cylinder was significantly reduced after 1 month, and this was maintained up to 3 months of follow-up. No significant change was detected in this parameter after 3 months. The sphere experienced no significant change between any visits. Higher-order aberrations did not change significantly during the follow-up period. No patients lost Snellen acuity,

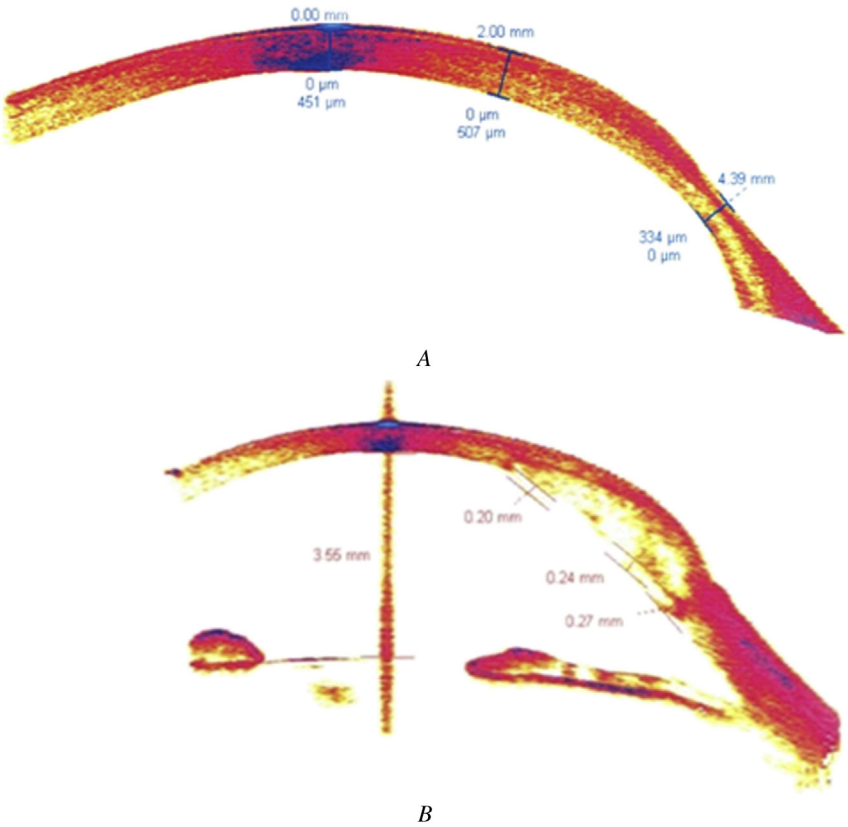

Figure 4. Preoperative (*A*) and 3 months postoperative (*B*) Visante anterior segment optical coherence tomography imaging of a patient having intrastromal lamellar keratoplasty.

and no intraoperative or postoperative complications occurred.

DISCUSSION

Most early PMD patients can be treated by nonsurgical methods such as spectacles and RGP contact lenses.[1,2] Surgical therapies such as collagen cross-linking (CXL) and simultaneous photorefractive keratectomy and CXL are suggested for early PMD, as they have been shown to stop the disease progression and corneal thinning.[8–10] As there is yet no consensus about surgical therapies for advanced PMD, many procedures have been suggested.[1] These procedures and their possible side effects are listed in Table 2 (except for ICRS and toric phakic intraocular lenses, which are not discussed here).[1,3–7,11–14]

Because of the insertion of the donor stromal tissue into an intrastromal pocket in this technique, the risk for limbal stem cell deficiency and corneal vascularization will decrease compared with the risk in other keratoplasty techniques (including

Table 1. Visual and refractive outcomes before and after intrastromal lamellar keratoplasty for treatment of PMD.

Parameter	Preop	1 Mo	3 Mo	6 Mo	12 Mo	*P* Value*
UDVA (logMAR)	0.57 ± 0.07	0.64 ± 0.16	0.55 ± 0.13	0.51 ± 0.14	0.42 ± 0.13	.04
CDVA (logMAR)	0.45 ± 0.12	0.56 ± 0.19	0.5 ± 0.16	0.47 ± 0.15	0.32 ± 0.11	.03
Sphere (D)	−2.4 ± 2.8	−2.6 ± 2.77	−2.2 ± 2.9	−1.9 ± 2.9	−2.00 ± 2.28	.09
Cylinder (D)	−5.52 ± 1.55	−4.87 ± 1.37	−4.4 ± 1.3	−4.6 ± 1.4	−4.65 ± 1.32	.04
HOAs	3.75 ± 0.77	4.25 ± 0.72	3.32 ± 0.75	3.27 ± 0.71	3.32 ± 0.74	.07
Coma	2.84 ± 0.61	3.24 ± 0.58	3.7 ± 0.61	3.75 ± 0.61	3.5 ± 0.59	.1
Spherical ab	0.82 ± 0.5	1.11 ± 0.48	1.01 ± 0.46	0.96 ± 0.49	1.09 ± 0.47	.1

CDVA = corrected distance visual acuity; HOAs = higher-order aberrations (root mean square); logMAR = logarithm of the minimal angle of resolution; PMD = pellucid marginal degeneration; Spherical ab = spherical aberrations (root mean square); UDVA = uncorrected distance visual acuity

Results are shown as mean ± standard deviation.
*Significance of changes between preoperative values and 1-year postoperative values.

Table 2. Surgical methods for advanced PMD and their possible side effects.

Surgery	Sample Size	Mean Follow-up	Last Follow-up Result	Possible Complications
Standard PKP[1,3,A]	3 eyes	66 mo	Mean residual cylinder: 4.63 D even after 66 mo; mean CDVA 6/15[1]	Poor visual outcomes because of proximity of the thinnest ectatic point to limbus, wound dehiscence, other graft complication like different forms of rejection and infections[1,A]
Inferiorly decentered normal size graft[6,A]	NA	NA	NA	Increased postop astigmatism, increased rejection risk, increased corneal vascularization risk
Large diameter grafts[1,7,12,A]	12 eyes (11 patients)	3 y	Final keratometric astigmatism 2.46 D (range 0.00, 5.25 D)[12]	Increased rejection risk (endothelial allograft rejection occurred in 64% in Varley study but no graft failure was reported), increased corneal vascularization risk
DALK[7]	16 eyes (16 patients)	14.6 ± 8.2 mo	Significant improvement in postoperative sphere ($P<.035$), cylinder ($P<.001$), and SE ($P<.02$) compared with preop	Same as PKP (except less endothelial cell loss and no endothelial rejection), questionable long term effects[1,7]
Lamellar crescentic corneal wedge resection[4,5]	15 eyes (9 patients)[4]	35 mo	Mean astigmatism 16.00 D at 6 wk, 10.50 D at 6 mo, and 4.30 D after 2 years; CDVA 20/40 in 71% of eyes at final follow-up	Wound dehiscence, short standing effects, and high recurrence rate,[A] prolonged visual recovery,[4] Inferior pannus[5]
	10 eyes (9 patients)[5]	59 mo	Mean postop (5.4 mo) astigmatism 1.4 D; long-term astigmatic drift noted (mean 2.1 D)	
Conductive lamellar thermokeratoplasty[1,11]	1 eye	50.25 mo	Preop astigmatism 20.5 D, 2-wk postop 3.50 D, last follow up 6.00 D	Poor visual outcomes[1,11]
Tuck-in lamellar keratoplasty[3,13]	12 eyes (12 patients)	1.7 y	50 % had CDVA >20/60, all had CDVA >20/80; astigmatism decreased from 5.93 D preop to 3.23 D at last follow up ($P=.037$)[13]	Same as DALK (except less limbal stem cell deficiency and more tectonic peripheral protection)[1,3,A]
Crescentic lamellar keratoplasty[1,14,A]	12 eyes	7–21 mo	Postop VA was statistically better than preop ($P<.05$)[14]	High postoperative astigmatism which may necessitate central corneal grafting (simultaneously or followed by each other)[1,A,6]
Inferior peripheral crescentic lamellar keratoplasty followed by central PKP[1,A]	NA	NA	NA	Two separate surgeries, higher rejection risk because of 2 different donor corneas[A,6]
Simultaneous inferior peripheral crescentic lamellar keratoplasty and central PKP[6]	5 patients	4 y	Mean visual rehabilitation time 9.92 mo; astigmatism range at the end of this period 0.3 D to 5.3 D Tendency to increase astigmatism after the rehabilitation period noted	Same as PKP but less tendency to increase in astigmatism, cataract, and IOP rise due to long-term corticosteroid, technically complex procedure[6]

CDVA = corrected distance visual acuity; DALK = deep anterior lamellar keratoplasty; NA = not available; PMD = pellucid marginal degeneration; PKP = penetrating keratoplasty; VA = visual acuity

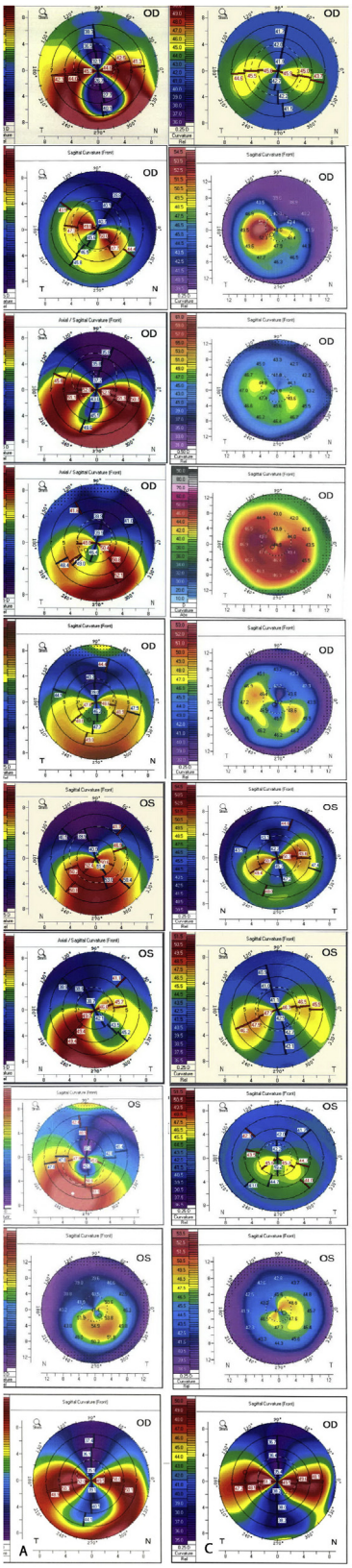

Figure 5. Preoperative (*left*) and postoperative (*right*) keratometry of 9 patients before and after intrastromal lamellar keratoplasty.

standard PKP, inferiorly decentered normal size grafts, and large diameter grafts). Moreover, there is no risk for endothelial graft rejection in this technique unlike in keratoplasty techniques. Furthermore, there is a high risk for wound dehiscence with normal size grafts due to the proximity of the thinnest ectatic point to the limbus. As there is no large full-thickness wound in this procedure, this complication is less likely to occur.

In this technique only 1 suture is needed for pocket closure, so the major problem of crescentic lamellar keratoplasty (high astigmatism induction), which necessitates central corneal regrafting (simultaneously or followed by each other), is not likely to occur. As the inferior cornea is no longer thin after the surgery, we may be able to perform refractive laser ablation to reduce residual refractive errors, although the reliability of laser refractive surgery has not been established in cases of irregular corneal contour.

As there is no risk for endothelial and epithelial graft rejection in this technique, there is no need to prescribe long-term corticosteroids, which can cause posterior subcapsular cataract and intraocular pressure elevation in other surgical procedures such as standard PKP, inferiorly decentered normal-sized grafts, large-diameter grafts, and simultaneous inferior peripheral crescentic lamellar keratoplasty and central PKP.[6]

Although the lamellar intrastromal technique avoids some risks, it has some potential risks including the risk for perforation during lamellar dissection through the thinnest portion of the cornea. Dissection through the thin stroma of the patient with PMD is difficult. As there is a small difference between the refractive index of the cornea and aqueous,[15] the estimation of the depth with the optical microscope is not accurate and there is substantial risk for inadvertent perforation into the anterior chamber. In case of perforation, the procedure should be converted to a PKP. There should be access to donor tissue with good quality endothelium during the procedure. Other possible risks include epithelial ingrowth, irregular astigmatism related to asymmetrical thickening, wrinkles in the lamellar graft, infection, stromal rejection, and extrusion of the graft.

Larger randomized studies with longer follow-up periods are needed to judge the efficacy of this technique. However, this technique appears promising and its effect seems to be comparable to those of more complex surgeries such as simultaneous inferior peripheral crescentic lamellar keratoplasty, central PKP, and DALK.[6,7]

WHAT WAS KNOWN

- Management of advanced PMD is a challenging procedure. Numerous treatment procedures have been described, and each has its own disadvantages.

WHAT THIS PAPER ADDS

- The proposed intrastromal lamellar keratoplasty seems to have promising results, especially in advanced cases in which other surgical procedures have less favorable outcomes.

REFERENCES

1. Jinabhai A, Radhakrishnan H, O'Donnell C. Pellucid corneal marginal degeneration: a review. Cont Lens Anterior Eye 2011; 34:56–63
2. Gruenauer-Kloevekorn C, Fischer U, Kloevekorn-Norgall K, Duncker GIW. Pellucid marginal corneal degeneration: evaluation of the corneal surface and contact lens fitting. Br J Ophthalmol 2006; 90:318–323. Available at: http://www.ncbi.nlm.nih.gov/pmc/articles/PMC1856967/pdf/318.pdf. Accessed September 4, 2014
3. Jhanji V, Vajpayee RB. Surgical management of ectatic corneal disorders. Hong Kong J Ophthalmol 2010; 14:20–25. Available at: http://www.cohk.org.hk/download/V14N1-p20.pdf. Accessed September 4, 2014
4. Javadi MA, Karimian F, Hosseinzadeh A, Noroozizadeh HM, Sa'eedifar MR, Rabie HM. Lamellar crescentic resection for pellucid marginal corneal degeneration. J Refract Surg 2004; 20:162–165
5. MacLean H, Robinson LP, Wechsler AW. Long-term results of corneal wedge excision for pellucid marginal degeneration. Eye 1997; 11:613–617. Available at: http://www.nature.com/eye/journal/v11/n5/pdf/eye1997164a.pdf. Accessed September 4, 2014
6. Rasheed K, Rabinowitz YS. Surgical treatment of advanced pellucid marginal degeneration. Ophthalmology 2000; 107:1836–1840
7. Al-Torbak AA. Deep anterior lamellar keratoplasty for pellucid marginal degeneration. Saudi J Ophthalmol 2013; 27:11–14. Available at: http://download.journals.elsevierhealth.com/pdfs/journals/1319-4534/PIIS131945341200046X.pdf. Accessed September 4, 2014
8. Piñero DP, Alio JL, Morbelli H, Uceda-Montanes A, El Kady B, Coskunseven E, Pascual I. Refractive and corneal aberrometric changes after intracorneal ring implantation in corneas with pellucid marginal degeneration. Ophthalmology 2009; 116:1656–1664
9. Kymionis GD, Karavitaki AE, Kounis GA, Portaliou DM, Yoo SH, Pallikaris IG. Management of pellucid marginal corneal degeneration with simultaneous customized photorefractive keratectomy and collagen crosslinking. J Cataract Refract Surg 2009; 35:1298–1301
10. Pron G, Ieraci L, Kaulback K. Medical Advisory Secretariat, Health Quality Ontario. Collagen cross-linking using riboflavin and ultraviolet-A for corneal thinning disorders: an evidence-based analysis. Ont Health Technol Assess Ser 2011; 11(5):1–89. Available at: http://www.ncbi.nlm.nih.gov/pmc/articles/PMC3377552/pdf/ohtas-11-89.pdf. Accessed September 4, 2014
11. Biswas S, Brahma A, Tromans C, Ridgway A. Management of pellucid marginal corneal degeneration. Eye 2000; 14:629–634. Available at: http://www.nature.com/eye/journal/v14/n4/pdf/eye2000155a.pdf. Accessed September 4, 2014
12. Varley GA, Macsai MS, Krachmer JH. The results of penetrating keratoplasty for pellucid marginal corneal degeneration. Am J Ophthalmol 1990; 110:149–152
13. Kaushal S, Jhanji V, Sharma N, Tandon R, Titiyal JS, Vajpayee RB. "Tuck In" lamellar keratoplasty (TILK) for corneal ectasias involving corneal periphery. Br J Ophthalmol 2008; 92:286–290
14. Huang T, Wang Y, Ji J, Gao N, Chen J. Evaluation of different types of lamellar keratoplasty for treatment of peripheral corneal perforation. Graefes Arch Clin Exp Ophthalmol 2008; 246:1123–1131
15. Katz M, Kruger PB. The human eye as an optical system. In: Tasman W, ed, Duane's Clinical Ophthalmology on CD Rom. Philadelphia, PA, Lippincott Williams & Wilkins, 2006; Vol 1. Chapter 33. Available at: http://www.eyecalcs.com/DWAN/pages/v1/v1c033.html. Accessed September 4, 2014

OTHER CITED MATERIAL

A. Rasheed, K. Pellucid Marginal Degeneration Treatment & Management. Medscape. Available at: http://www.medscape.com/viewarticle/738074. Accessed December 3, 2014.

First author:
Mahmoud Jabbarvand, MD

Ophthalmology Research Center, Farabi Eye Hospital, Tehran University of Medical Sciences, Tehran, Iran