

# Management of Corneal Astigmatism by Limbal Relaxing Incisions during Cataract Surgery

Mohammad Ali Zare, MD<sup>1</sup> • Mehdi Hosseini Tehrani, MD<sup>2</sup> • Mohsen Gohari, MD<sup>3</sup>  
Mahmood Jabbarvand, MD<sup>1</sup> • Mohammad Naser Hashemian, MD<sup>1</sup>  
Mehrdad Mohammadpour, MD<sup>4</sup> • Hadi Z-Mehrjerdi<sup>5</sup> • Nasim Siatiri<sup>6</sup>

---

## Abstract

**Purpose:** To evaluate the safety and efficacy of limbal relaxing incisions (LRIs) for corneal astigmatism correction during phacoemulsification

**Methods:** 24 eyes of 24 patients with the mean age of 65.71 years (range: 55 to 83 years) with senile cataracts and mean corneal astigmatism of  $1.9 \pm 0.83$  diopters (D) (range: 1.5 to 3.5 D) were included in this study. All LRIs were performed during phacoemulsification by one surgeon. Topography indices were recorded preoperatively and postoperatively in months 2 and 6.

**Results:** A statistically significant reduction in the mean corneal astigmatism was seen from  $1.9 \pm 0.83$  D preoperatively to  $1.4 \pm 0.84$  D and  $1.4 \pm 0.92$ , 2 months and 6 months postoperatively ( $P < 0.001$ ). Surgical induced astigmatism (SIA) (the amount and axis of astigmatism change induced by the surgery) was  $0.90 \pm 0.48$  at 2 months and  $0.96 \pm 0.59$  at 6 months. Correction index (CI) (calculated by determining the ratio SIA/ target induced astigmatism (TIA) was  $0.55 \pm 0.41$  and  $0.57 \pm 0.32$  at 2 and 6 months, respectively. Index of success (IOS) (ratio of topographic residual astigmatism and TIA) was measured  $0.44 \pm 0.41$  and  $0.47 \pm 0.32$  at months 2 and 6 correspondingly.

**Conclusion:** Combined LRI and phacoemulsification appears to be safe and fairly effective to correct mild to moderate corneal astigmatism. However, under correction is a common limitation that may be further managed by modified nomograms in future studies.

**Keywords:** Corneal Astigmatism, Limbal Relaxing Incision, Phacoemulsification

*Iranian Journal of Ophthalmology 2010;22(1):15-20 © 2010 by the Iranian Society of Ophthalmology*

---

1. Associate Professor of Ophthalmology, Eye Research Center, Farabi Eye Hospital, Tehran University of Medical Sciences
2. Professor of Ophthalmology, Eye Research Center, Farabi Eye Hospital, Tehran University of Medical Sciences
3. Resident in Ophthalmology, Eye Research Center, Farabi Eye Hospital, Tehran University of Medical Sciences
4. Ophthalmologist. Cornea Specialist, Eye Research Center, Farabi Eye Hospital, Tehran University of Medical Sciences
5. Medical Student, Tehran University of Medical Sciences
6. Medical Student, Shahid Beheshti University of Medical Sciences

Received: July 9, 2009

Accepted: December 31, 2009

There is no financial interest for the authors in any methods or materials mentioned in this article.

Correspondence to: Mehrdad Mohammadpour, MD

Eye Research Center, Farabi Eye Hospital, Tehran, Iran, Tel:+98 21 55414941-6, Email: mahammadpour@yahoo.com

## Introduction

Cataract surgery is the most successful and most commonly performed ophthalmic procedure in the modern medical world.<sup>1,2</sup>

An increasingly important goal of modern cataract and implant surgery is to obtain the most desirable refractive outcomes for the patients and to decrease their dependence upon spectacle corrections.<sup>3</sup> Novel techniques of cataract surgery to correct preexisting astigmatism are presented. Hence, the uncorrected visual outcome of cataract patients has been improved and better refractive correction is possible now.<sup>1,4,5</sup>

In order to achieve better visual results, the effect of postoperative astigmatism should be minimized through several techniques including intraoperative relaxing incisions, toric intraocular lens implants (IOL) implantation or postoperative vision correction by ablative refractive surgery by excimer laser; each with its own advantages and disadvantages.

Herein, we report the safety and efficacy of limbal relaxing incisions (LRIs) for correction of pre-existing corneal astigmatism during phacoemulsification.

## Methods

This prospective study was performed at department of ophthalmology of Farabi Eye Hospital, Tehran University of Medical Sciences from September 2007 to February 2008. Patients with senile cataracts and significant corneal astigmatism were included in this study. Informed consent was obtained from patients and the institute review board of ophthalmic research center approved the whole study.

The study's inclusion criteria were cataract patients aged  $\geq 50$  years and 1.5 to 3.5 diopters (D) of regular corneal astigmatism documented by corneal topography.

Exclusion criteria were previous ocular surgery, ocular trauma, pre-existing ocular disease, high intraocular pressure (IOP), corneal opacity, strabismus, amblyopia, diabetes mellitus and irregular astigmatism.

All patients underwent the ophthalmic examinations that included uncorrected visual acuity (UCVA) and best corrected visual acuity (BCVA), manifest refraction, anterior segment slit-lamp biomicroscopy, applanation

tonometry, indirect ophthalmoscopy, corneal topography (Astramax, LaserSight Technologies, Inc., Winter Park, Florida), limbal pachymetry (Tomy, Japan) and ultrasound biometry (Nidek, US, UF 2500, Japan). Phacoemulsification with concomitant LRIs was performed in 24 eyes by one surgeon. Patients were evaluated in follow-up examinations at months 2 and 6 and their data were evaluated.

## Surgeries

All surgeries were performed by one surgeon. SRK-T formula was used for all patients for IOL power calculation. Cataract surgery was performed under retro bulbar anesthesia. Acrylic foldable IOLs (Alcon, SA 60 AT, USA) were implanted through a 2.8 mm temporal clear corneal incision without enlargement using the injector for all eyes.

Before surgery, 6 and 12 o'clock position of cornea were marked while the patient was sitting upright. The steepest meridian was marked at the beginning of surgery, on which LRIs were made according to the modified Gills nomogram (Table 1).

All LRIs were placed inside the surgical limbus at a depth of 600  $\mu\text{m}$  before phacoemulsification with the LRI knife determined for 600  $\mu\text{m}$  (Figure 1).

For patients with against-the-rule astigmatism (steep corneal meridian within 20 degrees around the 180 degree on corneal topography), the temporal hinge incision for phacoemulsification was oriented to align with placement of the LRI. A second LRI was performed on the nasal side before phacoemulsification. After IOL implantation and before removal of viscoelastic material, the original minimal LRI was extended according to the nomogram. In eyes with with-the-rule astigmatism, paired LRIs were placed on the steep meridian before phacoemulsification as dictated by modified Gills nomogram (Table 1).

## Measures

The effectiveness of LRI was evaluated by comparing pre- and postoperative topographic astigmatism.<sup>16</sup> Effectiveness was analyzed using the mean and standard deviation of the postoperative topographic astigmatism at months 2 and 6 after surgery. The vector

analysis method was used to evaluate the efficacy of astigmatic correction (method of Kaye and Patterson).<sup>17</sup>

The safety of the LRI procedure was evaluated by recording of the intra operative and postoperative complications and subjective symptoms. Stability of procedure

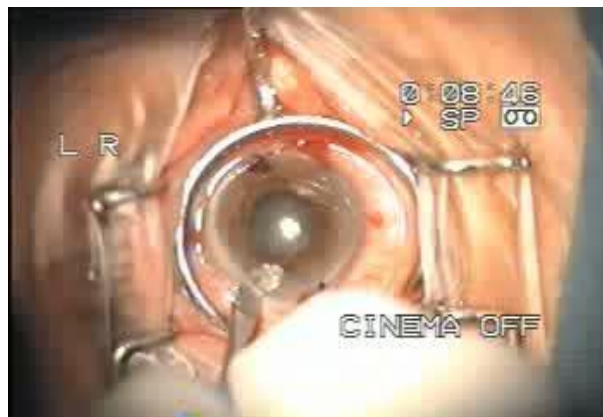was evaluated by the variability of the mean topographic astigmatism through 2<sup>nd</sup> and 6<sup>th</sup> months postoperative follow-up examinations (Figure 2).

Paired T-test was performed for statistical analysis and  $P \leq 0.05$  was considered statistically significant.

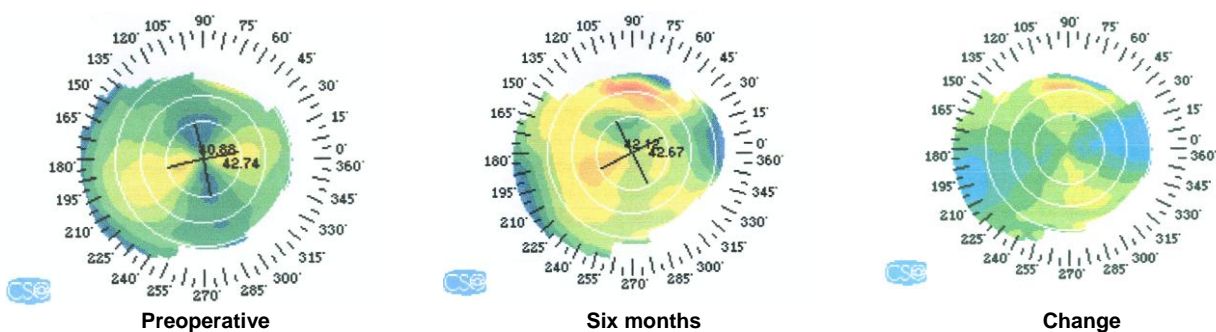
**Table 1.** Modified Gills nomogram indicating the degrees of arc incised with paired LRIs centered on the steep axis. The length is titrated by keratometric cylinder and patient age; the incision depth is set at 600µm.

Preoperative cylinder	Age (year)						
	30- 40	41-50	51-60	61-70	71-80	81-90	≥91
WTR astigmatism*	Degree of ARC						
1.50 to 2.25 D	60	55	50	45	40	35	30
2.50 to 3.00 D	70	65	60	55	50	45	40
≥ 3.25 D	80	75	70	65	60	55	45
ATR astigmatism†							
1.50 to 2.00 D	70	65	60	55	45	30	30
2.25 to 2.75 D	90	80	70	60	50	45	40
≥ 3.00 D	90	90	85	70	60	50	45

WTR: With the rule  
 ATR: Against the rule  
 \*: Steepest keratometry reading 46 to 135 degrees  
 †: Steepest keratometry reading 0 to 45 degrees or 136 to 180 degrees; the temporal incision includes the cataract incision.



**Figure 1.** All LRIs were placed inside the surgical limbus at a depth of 600 µm before phacoemulsification with the LRI knife determined for 600 µm as shown in this figure.



**Figure 2.** Preoperative and six months postoperative topography of a patient with preoperative corneal astigmatism and the difference map showing the effect of LRI

## Results

LRI was performed in 24 eyes (13 right eyes and 11 left eyes) of 24 patients. Mean patients age was  $65.7 \pm 7.9$  years (range: 55 to 83).

Data analysis demonstrated statistically significant reduction in the mean topographic astigmatism in the LRI eyes from  $1.9 \pm 0.83$  D (range: 1.40 to 3.20) preoperatively to  $1.40 \pm 0.84$  D (range: 0.50 to 2.60) and  $1.4 \pm 0.92$  D (range: 0.50 to 2.50) in 2nd and 6th postoperative months, respectively ( $P < 0.001$ ). There was no statistically significant difference between mean astigmatism at 2 months and 6 months after LRI ( $P = 0.91$ ) (Table 2).

**Table 2.** Vector analysis of postoperative astigmatism for eyes that underwent combined phacoemulsification and LRI (2 months and 6 months follow-up) (mean  $\pm$  SD)

	2 months postop.	6 months postop.
SIA	$0.9 \pm 0.48$	$0.96 \pm 0.59$
TIA	$1.9 \pm 0.83$	$1.9 \pm 0.83$
CI	$0.55 \pm 0.41$	$0.57 \pm 0.32$
IOS	$0.44 \pm 0.41$	$0.47 \pm 0.32$

SIA: Surgical induced astigmatism (the amount and axis of astigmatism change induced by the surgery)

TIA: Target induced astigmatism (the astigmatism changes that the surgery was intended to induce)

CI: Correction index (calculated by determining the ratio SIA/TIA [CI > 1 is considered overcorrection, and CI < 1 indicates under correction])

IOS: Index of success (ratio of topographic residual astigmatism and TIA)

UCVA was equal to 0.5 or more than 0.5 in 75% (18 cases) at month 2 after LRI, following 87% (21 cases) of patients at month 6 postoperatively. No patient lost any lines of UCVA or BCVA, which cannot be attributed solely to LRI efficacy as simultaneous cataract surgery was performed.

BCVA showed significant improvement at 2-month and 6-month follow-up evaluation. Average preoperative BCVA was  $0.17 \pm 0.11$  reaching  $0.74 \pm 0.22$  and  $0.82 \pm 0.18$ , 2 and 6 months after LRI, respectively ( $P < 0.001$ ). BCVA was  $\geq 0.7$  in 79% of patients 6 months after LRI that might mostly be due to the cataract extraction and IOL implantation and not a consequence of the LRI surgery.

There was no intraoperative complication or postoperative subjective complaints (such as halo or glare) in our patients.

## Discussion

Visual recovery and satisfaction of patients who underwent phacoemulsification is closely related to the appropriate IOL power calculation and management of postoperative astigmatism.<sup>6-10</sup> Among patients undergoing cataract surgery, 15-20% have significant corneal astigmatism ranging from 1 to 3 D.<sup>6</sup> With the introduction of aspherical intraocular lens (IOLs) as an integral part of cataract surgery, better formula for IOL power calculation, and eliminating lenticular astigmatism by removing the lens by cataract extraction, the major source of postoperative refractive astigmatism is the corneal astigmatism.<sup>11</sup>

There are several options to reduce the postoperative astigmatism including intraoperative relaxing incisions, toric IOL implantation or postoperative vision correction by ablative refractive surgery by excimer laser each with its own benefits and drawbacks. Toric IOLs are rather expensive. Moreover, if postoperative rotation of the IOL occurs, there would be a significant induced astigmatism. Excimer laser vision correction after cataract surgery needs an additional operation with high expenses, possible complications and limitations in patients with thin cornea.<sup>12-15</sup>

LRIs have been used to correct preexisting astigmatism at the time of cataract surgery. Simultaneously, one can benefit of lower costs and easy performance with minimal learning curve, without overcorrection. However, the predictability, stability and range of correction are rather limited.<sup>12-14</sup>

According to Gills and Guyton LRIs are more effective in eyes with low to moderate, rather than high astigmatism.<sup>12</sup> LRIs also appear to cause less distortion and irregularity at the limbus. They can provide more rapid postoperative visual acuity (VA) in compare with clear corneal incisions with less risk of glare and discomfort.<sup>12,15</sup>

In this study, range of astigmatism correction is evaluated using vector analysis of surgical induced astigmatism (SIA) vector and target induced astigmatism (TIA) vector. SIA vector is the amount and axis of

astigmatic change that the surgery actually induced.

TIA vector is astigmatic change (by magnitude and axis) that the surgery was intended to induce. Correction index (CI) is calculated by dividing SIA by TIA. The CI is preferably equal to 1.0. In overcorrection CI is more than 1, and less than 1, in the case of under correction. Difference vector (DV) is calculated by TIA-SIA. Index of success (IOS) is calculated by dividing the DV by the TIA vector. The IOS is a relative measure of success and is preferably zero.<sup>23</sup>

Considering the above mentioned ratios, our study demonstrated that use of LRIs during phacoemulsification, reduce corneal astigmatism; however, there was a trend for under correction. Under correction was not uncommon in previous reports.<sup>18,19</sup> Budak et al studied 22 patients.<sup>20</sup> They found a 44% reduction of astigmatism in eyes treated with LRI during phacoemulsification using the Gills nomogram.

In study of Carvalho et al<sup>6</sup> a statistically significant reduction in the mean topographic astigmatism was seen in the cataract LRI eyes from  $1.93 \pm 0.58$  D preoperatively to  $1.02 \pm 0.60$  D 6 months postoperatively ( $P < 0.05$ ).

Multiple factors might cause under correction of astigmatism in patients who are treated with phacoemulsification and LRIs. We minimized the surgeon factor by performing all

operations by only one surgeon. Another cause may be the improper position of blade (Oblique incision rather than perpendicular incision on the limbus, that may result in the wrong depth causing under correction).<sup>21</sup> Under correction may be related to area of limbal incision that is far from the corneal center.<sup>22</sup> However, more central clear corneal incisions may cause more glare and higher order aberrations for the patients.

## Conclusion

In summary, simultaneous LRI during phacoemulsification surgery appears to be safe and fairly effective to correct mild to moderate amounts of corneal astigmatism. Under correction is a common limitation that may be further managed by modified nomograms in future studies adjusted by the surgeon factors. Apart from the patient age, multiple factors including ethnicity, gender, corneal limbal thickness, course of postoperative steroid regimen and surgeon factors should be considered for adjustment of future nomograms. We recommend surgeons to apply nomograms that take patient age and size of LRI in millimeter to decrease preoperative corneal astigmatism. It seems that LRI incisions can not full correct but would cause more acceptable reduction in the preoperative corneal astigmatism.

## References

1. Kershner RM. Refractive cataract surgery. *Curr Opin Ophthalmol* 1998;9(1):46-54.
2. Chen WR, Ye HH, Qian YY, et al. Comparison of higher-order aberrations and contrast sensitivity between Tecnis Z9001 and CeeOn 911A intraocular lenses: A prospective randomized study. *Chine Med J (Engl)* 2006;119(21):1779-84.
3. Nichamin LD. Treating astigmatism at the time of cataract surgery. *Curr Opin Ophthalmol* 2003;14(1):35-8.
4. Nichamin LD. Astigmatism control. *Ophthalmol Clin North Am* 2006;19(4):485-93.
5. Alastrué V, Calvo B, Peña E, Doblare M. Biomechanical modeling of refractive corneal surgery. *J Biomech Eng.* 2006;128(1):150-60.
6. Carvalho MJ, Suzuki SH, Freitas LL, et al. Limbal relaxing incisions to correct corneal astigmatism during phacoemulsification. *J Refract Surg* 2007;23(5):499-504.
7. Hoffer KJ. Biometry of 7,500 cataractous eyes. *Am J Ophthalmol* 1980;90(3):360-8.
8. Oshika T, Yoshitomi F, Fukuyama M, et al. Radial keratotomy to treat myopic refractive error after cataract surgery. *J Cataract Refract Surg.* 1999;25(1):50-5.
9. Packer M, Fine IH, Hoffman RS, et al. Immersion A-scan compared with partial coherence interferometry: outcomes analysis. *J Cataract Refract Surg* 2002;28(2):239-42.

10. Murphy C, Tuft SJ, Minassian DC. Refractive error and visual outcome after cataract extraction. *J Cataract Refract Surg* 2002;28(1):62-6.
11. Kaufmann C, Peter J, Ooi K, et al. Limbal relaxing incisions versus on-axis incisions to reduce corneal astigmatism at the time of cataract surgery. *J cataract Refract Surg* 2005;31(12):2261-5.
12. Bayramlar HH, Dağlıoğlu MC, Borazan M. Limbal relaxing incisions for primary mixed astigmatism and mixed astigmatism after cataract surgery. *J Cataract Refract surg* 2003;29(4):723-8.
13. Budak K, Friedman NJ, Koch DD. Limbal relaxing incisions with cataract surgery. *J Cataract Refract Surg* 1998;24(4):503-8.
14. Müller-Jensen K, Fischer P, Siepe U. Limbal relaxing incisions to correct astigmatism in clear corneal cataract surgery. *J Refract Surg* 1999;15(5):586-9.
15. Gills JP, Gayton JL. Reducing pre-existing astigmatism. In: Gills JP, Fenzle R, Martin RG, eds, *cataract surgery; the state of the art*. Thorofare, NJ, Slack, 1998;53-66.
16. Holladay JT. Proper method for calculating average visual acuity. *J Refract Surg*. 1997;13(4):388-91.
17. Kaye SB, Patterson A. Analyzing refractive changes after anterior segment surgery. *J Cataract Refract Surg* 2001;27(1):50-60.
18. Osher RH. Paired transverse relaxing keratotomy: a combined technique for reducing astigmatism. *J Cataract Refract Surg* 1989;15(1):32-7.
19. Oshika T, Shimazaki J, Yoshitomi F, et al. Arcuate keratotomy to treat corneal astigmatism after cataract surgery: a prospective evaluation of predictability and effectiveness. *Ophthalmology* 1998;105(11):2012-6.
20. Budak K, Yilmaz G, Aslan BS, Duman S. Limbal relaxing incisions in congenital astigmatism: 6 month follow-up. *J Cataract Refract Surg* 2001;27(5):715-9.
21. Akura J, Matsuura K, Hatta S, et al. A new concept for the correction of astigmatism: full-arc, depth-dependent astigmatic keratotomy. *Ophthalmology* 2000;107(1):95-104.
22. Waring Go 3rd, Lynn MJ, McDonnell PJ. Results of the prospective evaluation of radial keratotomy (PERK) study 10 years after surgery. *Arch Ophthalmol* 1994;112(10):1298-308.
23. Alpíns N. Astigmatism analysis by the Alpíns method. *J Cataract Refract Surg* 2001;27(1):31-49.