

---

# *Nattrassia mangiferae* keratitis after laser in situ keratomileusis

Mahmood Jabbarvand, MD, Mohammad Rasool Hashemian, MD, Zohreh Abedinifar, MS, Ali Amini, MD

---

A 32-year-old man had photophobia and blurred vision 2 weeks after uneventful laser in situ keratomileusis to correct myopia. He was treated with steroids for suspected diffuse lamellar keratitis, antiherpetics, and antibiotic eyedrops, but the condition worsened and the patient developed further blurred vision, an inflamed eye, and pain. When referred to us, the patient had an extensive corneal ulcer with hypopyon and mycelia were reported in scrapings of the ulcer bed. *Nattrassia mangiferae* (*Hendersonula toruloidea*) was cultured from the specimen. The patient was treated with antifungal agents and 2 penetrating keratoplasties. At the last examination, the uncorrected visual acuity was 20/200.

*J Cataract Refract Surg* 2004; 30:268–272 © 2004 ASCRS and ESCRS

---

Refractive surgery has evolved and gained wide acceptance worldwide. Laser in situ keratomileusis (LASIK) is the most commonly used surgical technique for refractive errors.<sup>1</sup> Infectious keratitis after LASIK, although rare (1/5000 to 1/10 000), is a serious and potentially sight-threatening complication.<sup>2–4</sup> Whereas mycobacterial species are emerging as the leading pathogens in post-LASIK infections,<sup>5–11</sup> few cases of fungal keratitis have been reported.<sup>12–17</sup> We describe the first case of fungal keratitis caused by *Nattrassia mangiferae* (*Hendersonula toruloidea*) after an uneventful LASIK procedure.

## Case Report

A 32-year-old healthy man had bilateral simultaneous LASIK for myopia of  $-4.50$  diopters (D) in the right eye and  $-4.00$  D in the left eye. After surgery, the patient was started on topical antibiotics (chloramphenicol 0.5% eyedrops every 4 hours) and betamethasone every 4 hours. Two

weeks after the procedure, the patient complained of photophobia and blurred vision in the right eye. His surgeon increased the dosage of topical antibiotics (chloramphenicol eyedrops every 2 hours) and continued the steroid eyedrops for 1 week. Betamethasone eyedrops were discontinued because of a white corneal infiltrate that appeared during this time, and ciprofloxacin 0.3% eyedrops every 2 hours were started. This new regimen was tapered during the next 2 months. The patient still complained of tearing, photophobia, red eye, and deteriorating vision in the right eye 3 months after the procedure. Herpetic keratitis was suspected and a new treatment was started: topical trifluridine 1% eyedrops every 2 hours and oral acyclovir 2 g/day. The patient showed no improvement.

When the patient was referred to us 4 months after the procedure, visual acuity was hand motions in the right eye and 20/20 in the left eye. In the right eye, there was lid edema with severe conjunctival and pericorneal injection. As the patient's file could not be obtained from the surgeon, it was not known when the epithelial defect occurred or the level of corneal infiltration. There was an epithelial defect measuring 7.0 mm  $\times$  7.0 mm plus mucopurulent material covering almost the entire surface of the cornea, with deep central infiltration and an abscess with indistinct margins involving the whole cornea (Figure 1). There was severe reaction in the anterior chamber and hypopyon 1.0 mm in height. Lens and fundus examinations were not possible because of opaque media, but B-scan showed no involvement of the vitreous and retina. Specimens were collected by scraping the margins of the abscess and bed of the corneal flap using a #15 blade under the slitlamp and submitted for bacteriological and mycological analysis. Gram and Giemsa

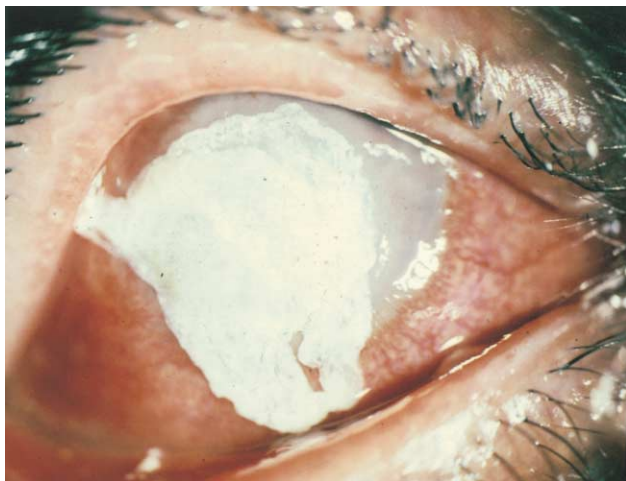---

Accepted for publication May 30, 2003.

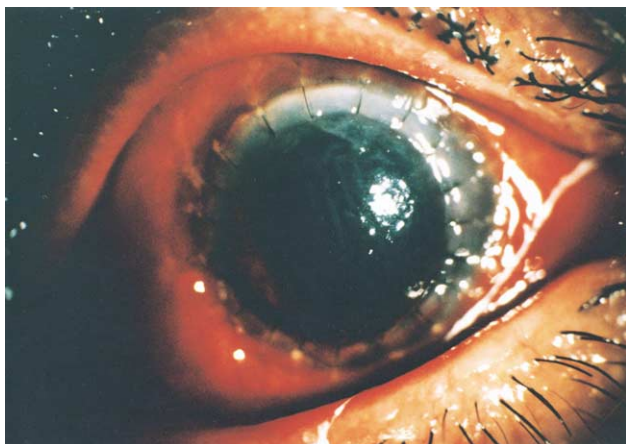
From Farabi Eye Hospital, Tehran University of Medical Sciences, Tehran, Iran.

None of the authors has a financial or proprietary interest in any material or method mentioned.

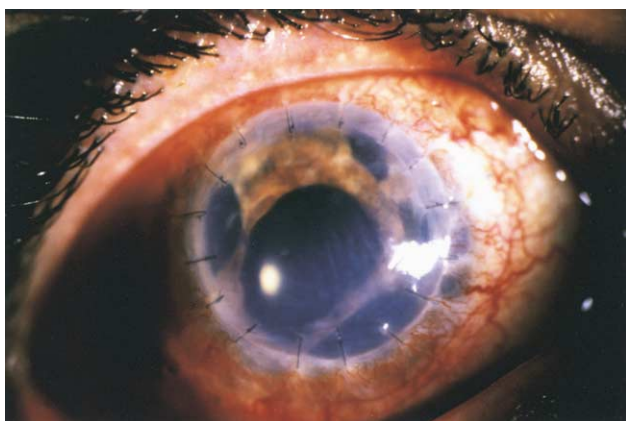
Reprint requests to Mohammad Rasool Hashemian, MD, Farabi Eye Hospital, Qazvin Square, Tehran, Iran. E-mail: r\_hash\_oph@yahoo.com.



**Figure 1.** (Jabbarvand) Corneal abscess with mucopurulent discharge involving almost the entire corneal surface.



**Figure 2.** (Jabbarvand) The first procedure comprised cataract extraction and PKP.



**Figure 3.** (Jabbarvand) The second procedure comprised anterior vitrectomy, PKP, and scleral fixation of an IOL.

stains showed hyphae. Antifungal treatment that included local natamycin 5% every hour, homatropine 2% eyedrops 4 times a day, and ketoconazole tablets 400 mg/day was started.

*Natrassia mangiferae* was detected in the cultures 4 days later. Two weeks after medical therapy, considering the extent and depth of the ulcer, limbal involvement, and unsatisfactory response to medical treatment, a large therapeutic penetrating keratoplasty (PKP) with a 9.5 mm donor size was done. When the corneal button was removed, the lens appeared dense enough to justify a combined procedure (extracapsular cataract extraction plus PKP [Figure 2]). The corneal button was cultured, and *N mangiferae* was confirmed.

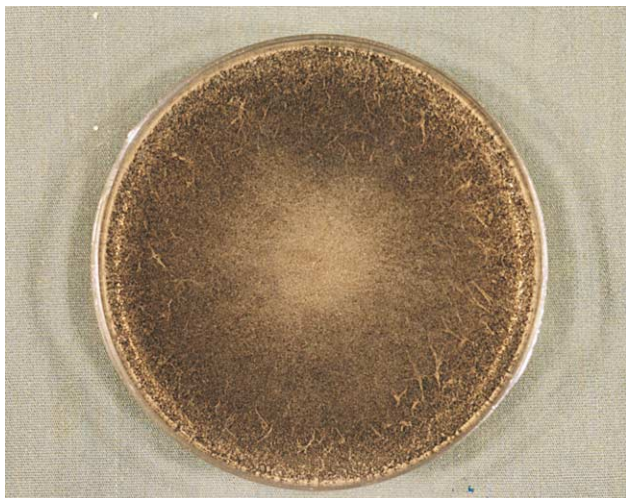
Postoperatively, the patient was treated for 6 weeks with natamycin 5% every 2 hours, atropine 1% every 4 hours, timolol 0.5% eyedrops twice a day, and betamethasone eyedrops twice a day for severe anterior chamber inflammation. Six weeks after the procedure, there were signs of endothelial and stromal rejection such as epithelial and stromal edema. Intraocular pressure was normal. The new regimen was betamethasone eyedrops every 2 hours, prednisolone tablets 75 mg/day, and antifungal therapy that was continued and later tapered. The patient's condition worsened as epithelial and stromal edema, bullae, and deep vascularization around the cornea with extensive peripheral anterior synechias developed.

The condition was managed by medication for 6 months after the combined procedure. A second optical PKP with an 8.0 mm donor size was performed because of extensive deep vascularization of the interface; anterior vitrectomy, pupiloplasty, and scleral fixation of a posterior chamber intraocular lens were done (Figure 3). Culture of the second corneal button showed no fungal growth. Postoperative medications included betamethasone eyedrops every 2 hours, atropine 1% eyedrops 4 times a day, and prednisolone tablets 50 mg/day. Two weeks later, signs of epithelial and endothelial rejection appeared. Medications such as betamethasone eyedrops every 2 hours, atropine 1% eyedrops 4 times a day, prednisolone tablets 75 mg/day, and cyclosporin capsules 50 mg/day were instituted. Medications were tapered, and decreased signs of rejection were observed.

At the last examination, the uncorrected visual acuity (UCVA) was 20/200 because of high irregular astigmatism and mild corneal edema; the corneal graft was moderately clear with no anterior chamber reaction. Otherwise, the ocular examination was normal.

### *Mycology*

Scrapings of the right cornea showed fungal hyphae in Giemsa and gram-stained smears. Scrapings were plated on blood agar, chocolate agar, and Sabouraud dextrose agar at 25°C and 37°C for fungal and bacterial agents, respectively. Within 2 to 3 days of incubation, woolly black colonies were

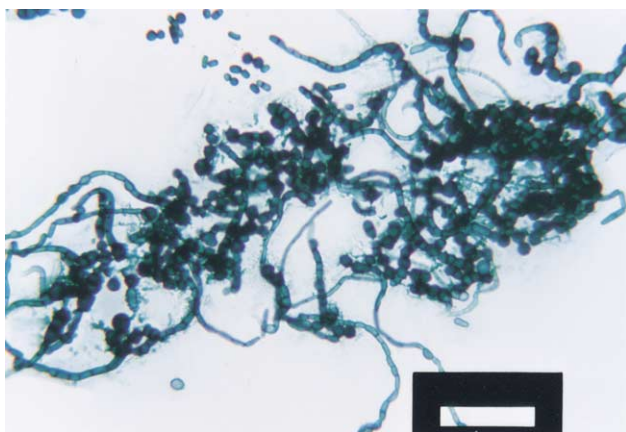


**Figure 4.** (Jabbarvand) Woolly black fungal colonies after 3 days of incubation.

observed on the plates (Figure 4). Bacteria were not isolated. The fungal colonies were inoculated onto potato dextrose agar and were inoculated at 25°C to 28°C. Potato flake agar slide cultures showed the mycelium to be composed of septate hyphae and single to 2-celled dematiaceous with thick-walled arthroconidia (Figure 5). The fungus was identified as *N mangiferae*, which was confirmed at the Fungology Department of the Faculty of Health, Tehran University of Medical Sciences.

## Discussion

Laser in situ keratomileusis has supplanted photorefractive keratectomy (PRK) as the procedure of choice to correct refractive errors because of faster visual rehabilitation, increased postoperative comfort, and rapid



**Figure 5.** (Jabbarvand) Septate hyphae (*N mangiferae*).

healing.<sup>1</sup> It also corrects up to 14.0 D of myopia and 6.0 D of astigmatism and causes minimal corneal haze.<sup>1</sup> However, it is a more invasive procedure than PRK and its complications can be sight threatening.<sup>18,19</sup>

Laser in situ keratomileusis has intraoperative and postoperative complications. One of the most serious postoperative complications is infectious keratitis. Its incidence has been estimated as 1 in 5000 procedures, compared with 1 in 1000 after PRK.<sup>20</sup> A literature review indicates that 41 eyes were reported to have microbial keratitis after LASIK.<sup>1</sup> Fungal keratitis after LASIK appears to be even rarer. To date, only 6 cases have been reported,<sup>2</sup> including infections with *Acremonium atrovireum*,<sup>12</sup> *Aspergillus flavus*,<sup>13</sup> *Aspergillus fumigatus*,<sup>14</sup> curvularia species,<sup>15</sup> *Fusarium solari*,<sup>16</sup> and *Scedosporium apiospermum*.<sup>17</sup> It is important to differentiate infectious from noninfectious etiologies when approaching post-LASIK keratitis. Smears and cultures, clinical examinations, and close follow-up are helpful in making the distinction.<sup>21</sup> In suspicious cases, the flap can be lifted and a specimen taken by scraping the bed.<sup>22</sup> Sometimes it may be necessary to take a biopsy from the ulcer bed.<sup>23</sup> In this case, it was impossible to determine the source of contamination, ie, whether it occurred intraoperatively or postoperatively. There was no history of ocular trauma, but unilateral ocular involvement is against the hypothesis of instrumental contamination because the same microkeratome was used in both eyes.<sup>24,25</sup>

Antibiotic sensitivity tests have not been standardized for fungi, and they are more difficult and less reliable than those for bacteria.<sup>26,27</sup> Late referral of our patient caused a delay in appropriate diagnosis and treatment. The extent of corneal involvement at the time of presentation hampered a satisfactory result despite flap irrigation and extensive debridement.<sup>28</sup> Cultures obtained from the scrapings of the ulcer bed showed *N mangiferae* growth. There have been no reports to date of ulcerative keratitis caused by this agent.

This fungus is a common cause of dermatomycosis and onychomycosis in patients living in tropical climates<sup>29,30</sup> and has been detected in patients emigrating from these areas. More recent instances of invasive disease from temperate regions, particularly in immunocompromised hosts, have been reported.<sup>31</sup>

In our case, medical therapy was not successful despite aggressive treatment (natamycin 5% eyedrops and ketoconazole tablets) and considering the extension to the anterior chamber and limbus, a large therapeutic PKP was necessary.<sup>26,29,30</sup> Of the 6 fungal keratitis cases after LASIK in the literature, PKP was inevitable in 4 cases.<sup>12-17</sup> Reports are varied in terms of final visual outcome. One patient with keratitis caused by *curvularia* species reported by Chung and coauthors<sup>15</sup> achieved a UCVA of 20/30 with medical treatment alone (natamycin 5% plus amphotericin B 0.15%). In another case caused by *A. atropisum* reported by Read and coauthors,<sup>12</sup> the best corrected visual acuity was 20/80 after medication plus a therapeutic PKP. We could anticipate failure and rejection of the corneal graft because of advanced lesion. The second PKP was performed after rejection occurred.

Early diagnosis and treatment of infectious keratitis after LASIK is an important prognostic factor, and one should consider the rare pathogen *N. mangiferae*, which has not been previously reported.

### References

1. Pushker N, Dada T, Sony P, et al. Microbial keratitis after laser in situ keratomileusis. *J Refract Surg* 2002; 18:280-286
2. Pache M, Schipper I, Flammer J, Meyer P. Unilateral fungal and mycobacterial keratitis after simultaneous laser in situ keratomileusis. *Cornea* 2003; 22:72-75
3. Machat JJ. LASIK complications. In: Machat JJ, Slade SG, Probst LE, eds, *The Art of LASIK*, 2nd ed. Thorofare, NJ, Slack, 1999; 371-415
4. Suarez E, Cardenas JJ. Intraoperative complications of LASIK. In: Buratto L, Brint SF, eds, *LASIK; Principles and Techniques*. Thorofare, NJ, Slack, 1998; 371-379
5. Reviglio V, Rodriguez ML, Picotti GS, et al. Mycobacterium chelonae keratitis following laser in situ keratomileusis. *J Refract Surg* 1998; 14:357-360
6. Chung MS, Goldstein MH, Driebe WT Jr, Schwartz BH. Mycobacterium chelonae keratitis after laser in situ keratomileusis successfully treated with medical therapy and flap removal. *Am J Ophthalmol* 2000; 129:382-384
7. Gelender H, Carter HL, Bowman B, et al. Mycobacterium keratitis after laser in situ keratomileusis. *J Refract Surg* 2000; 16:191-195
8. Kouyoumdjian GA, Forstot SL, Durairaj VD, Damiano RE. Infectious keratitis after laser refractive surgery. *Ophthalmology* 2001; 108:1266-1268
9. Garg P, Bansal AK, Sharma S, Vemuganti GK. Bilateral infectious keratitis after laser in situ keratomileusis; a case report and review of the literature. *Ophthalmology* 2001; 108:121-125
10. Solomon A, Karp CL, Miller D, et al. Mycobacterium interface keratitis after laser in situ keratomileusis. *Ophthalmology* 2001; 108:2201-2208
11. Chandra NS, Torres MF, Winthrop KL, et al. Cluster of Mycobacterium chelonae keratitis cases following laser in-situ keratomileusis. *Am J Ophthalmol* 2001; 132:819-830
12. Read RW, Chuck RSH, Rao NA, Smith RE. Traumatic Acremonium atropisum keratitis following laser-assisted in situ keratomileusis. *Arch Ophthalmol* 2000; 118:418-421
13. Sridhar MS, Garg P, Bansal AK, Gopinathan U. Aspergillus flavus keratitis after laser in situ keratomileusis. *Am J Ophthalmol* 2000; 129:802-804
14. Kuo IC, Margolis TP, Cevallos V, Hwang DG. Aspergillus fumigatus keratitis after laser in situ keratomileusis. *Cornea* 2001; 20:342-344
15. Chung MS, Goldstein MH, Driebe WT Jr, Schwartz B. Fungal keratitis after laser in situ keratomileusis: a case report. *Cornea* 2000; 19:236-237
16. Gupta V, Dada T, Vajpayee RB, et al. Polymicrobial keratitis after laser in situ keratomileusis. *J Refract Surg* 2001; 17:147-148
17. Sridhar MS, Garg P, Bansal AK, Sharma S. Fungal keratitis after laser in situ keratomileusis. *J Cataract Refract Surg* 2000; 26:613-615
18. American Academy of Ophthalmology. Basic and Clinical Science Course. Extended Disease and Cornea, Section 8. San Francisco, CA, AAO, 2002; 477
19. Mulhern MG, Condon PI, O'Keefe M. Endophthalmitis after astigmatic myopic laser in situ keratomileusis. *J Cataract Refract Surg* 1997; 23:948-950
20. Machat JJ. Excimer Laser Refractive Surgery: Practice and Principles. Thorofare, NJ, Slack, 1996; 359-400
21. Smith RJ, Maloney RK. Diffuse lamellar keratitis; a new syndrome in lamellar refractive surgery. *Ophthalmology* 1998; 105:1721-1726
22. Ishibashi Y, Kaufman HE. Corneal biopsy in the diagnosis of keratomycosis. *Am J Ophthalmol* 1996; 101:288-293
23. Alexandrakis G, Haimovici R, Miller D, Alfonso EC. Corneal biopsy in the management of progressive microbial keratitis. *Am J Ophthalmol* 2000; 129:571-577
24. Forster RK. Fungal keratitis and conjunctivitis; Clinical disease. In: Smolin G, Thoft RA, eds, *The Cornea; Scientific Foundations and Clinical Practice*, 3rd ed. Boston, MA, Little, Brown, 1994; 239-252
25. Kinota S, Wong KW, Biswas J, Rao NA. Changing patterns of infectious keratitis: overview of clinical and

- histopathological features of keratitis due to *Acanthamoeba* or atypical mycobacteria, and infectious crystalline keratopathy. *Indian J Ophthalmol* 1993; 41:3–14
26. O'Day DM, Akrabawi PL, Head WS, Ratner HB. Laboratory isolation techniques in human and experimental fungal infections. *Am J Ophthalmol* 1979; 87:688–693
  27. O'Day DM, Ray WA, Robinson RD, et al. In vitro and in vivo susceptibility of *Candida* keratitis to topical polyenes. *Invest Ophthalmol Vis Sci* 1987; 28:874–880
  28. Liesegang TJ. Fungal keratitis. In: Kaufman HE, Barron BA, McDonald MB, eds, *The Cornea*, 2nd ed. Boston, MA, Butterworth-Heinemann, 1998; 219–245
  29. Baban B, Choolaei A, Emami M, et al. The first survey of *Hendersonula toruloidea* as a human pathogen in Iran. *J Int Med Res* 1995; 23:123–125
  30. Lacaz CS, Pereira AD, Heins-Vaccari EM, et al. Onychomycosis caused by *Scytalidium dimidiatum*; report of two cases. Review of the taxonomy of the synanamorph and anamorph forms of this coelomycete. *Rev Inst Med Trop Sao Paulo* 1999; 41:319–323
  31. Sutton DA, Fothergill AW, Rinaldi MG. *Guide to Clinically Significant Fungi*. Baltimore, MD, Williams & Wilkins, 1998