

# Relationship between the GDx VCC and Stratus OCT in Primary Open Angle Glaucoma

Reza Zarei, MD<sup>1</sup> • Mohammad Soleimani, MD<sup>2</sup> • Sasan Moghimi, MD<sup>3</sup>  
Mohammad Yaser Kiarudi, MD<sup>2</sup> • Mahmoud Jabbarvand, MD<sup>1</sup>  
Yadollah Eslami, MD<sup>1</sup> • Ali Abdollahi, MD<sup>1</sup> • Mohammad Reza Panjtan Panah, MD<sup>4</sup>  
Heydar Amini, MD<sup>1</sup> • Ghasem Fakhraei, MD<sup>3</sup>

---

## Abstract

**Purpose:** To compare the ability of scanning laser polarimetry (GDx VCC), and optical coherence tomography (OCT) to discriminate eyes with primary open angle glaucoma (POAG) from normal eyes and to assess the relationship between their parameters

**Methods:** Eighty-seven glaucomatous eyes of 87 patients and 25 normal eyes were enrolled. The mean age of patients and normal group were  $54.96 \pm 18.34$  and  $50.02 \pm 20.15$ , respectively. All subjects underwent a full ophthalmic examination, automated perimetry, GDx VCC and OCT. Correlation coefficients between the parameters of OCT and GDx VCC were calculated. We calculated area under the receiver operating characteristic curve (AROC) for GDx VCC and OCT main parameters.

**Results:** Statistically significant correlations were observed between GDx VCC and OCT parameters. Pearson coefficients ranged from 0.731 for inferior average to -0.858 for nerve fiber indicator (NFI)/average thickness of OCT. The greatest area under AROC parameter in OCT (inferior average 0.97) had a lower area than that in GDx VCC (NFI; 0.99). There was a significant statistical correlation in all visual field (VF), GDx VCC, and OCT variables between two groups.

**Conclusion:** Many parameters of GDx VCC were significantly correlated with those of the OCT. Inferior average and NFI had the greatest area under AROC parameter in OCT and GDx VCC, respectively. NFI had high sensitivity and specificity for the diagnosis of POAG.

**Keywords:** Primary Open Angle Glaucoma, GDx, Optical Coherence Tomography, Retinal Nerve Fiber Layer

*Iranian Journal of Ophthalmology 2009;21(4):55-62 © 2009 by the Iranian Society of Ophthalmology*

---

- 
1. Associate Professor of Ophthalmology, Eye Research Center, Farabi Eye Hospital, Tehran University of Medical Sciences
  2. Resident in Ophthalmology, Eye Research Center, Farabi Eye Hospital, Tehran University of Medical Sciences
  3. Assistant Professor of Ophthalmology, Eye Research Center, Farabi Eye Hospital, Tehran University of Medical Sciences
  4. Fellowship in Glaucoma, Eye Research Center, Farabi Eye Hospital, Tehran University of Medical Sciences

Received: January 5, 2009

Accepted: July 16, 2009

Correspondence to: Sasan Moghimi, MD  
Eye Research Center, Farabi Eye Hospital, Tehran, Iran, Tel:+98 21 55414941-6, Email: sasanimii@yahoo.com

## Introduction

Glaucoma is an optic neuropathy with the loss of retinal ganglion cells and this loss clinically is defined by some thinning of the retinal nerve fiber layer (RNFL). Recently, several studies have designed to report the relationship between RNFL damage and visual function in glaucomatous optic neuropathy.<sup>1</sup>

Optical coherence tomography (OCT) and scanning laser polarimetry (SLP) are two techniques that measure peripapillary RNFL thickness. OCT can obtain a cross section of the retina with interferometry based on the reflectivity of the different layers of the retina. GDx VCC, the latest version of SLP, is based on a variable corneal compensation and estimates the thickness of RNFL by measuring the sum of retardation from ganglion cell axons.<sup>2-4</sup>

Several studies have shown relatively high diagnostic accuracy in detection of glaucoma with OCT and GDx VCC,<sup>5,6</sup> moreover there are few reports demonstrating that measurements between Stratus OCT and GDx VCC are correlated.<sup>7-10</sup> The purpose of this study was to investigate the relationship between Stratus OCT and GDx VCC in primary open angle glaucoma (POAG).

## Methods

A total of 87 glaucomatous eyes of 87 patients (one eye of each patient) meeting the inclusion criteria were included in this study. Informed consent was obtained from all patients. The diagnosis of glaucoma was based on the presence of typical glaucomatous optic disc damage on ophthalmoscopic examination (as determined by a glaucoma specialist, in glaucoma clinic). The presence of a glaucomatous visual field (VF) loss, as documented by the standard automated perimetry (SAP; Humphrey Field Analyzer II, 30-2 Swedish interactive threshold algorithm standard strategy; Carl Zeiss Meditec Inc., Dublin, California, USA), also provided a diagnosis of glaucoma.

Patients were defined as glaucoma when they showed at least two of the following criteria: glaucomatous VF defects based on the pattern standard deviation (PSD) and the mean deviation (MD) in SAP, ocular hypertension [intraocular pressure (IOP)>21

mmHg], and optic nerve head glaucomatous changes (disc asymmetry between the eyes that was <0.2, rim thinning, notching, excavation, or RNFL defect).

Other inclusion criteria were: best corrected visual acuity (BCVA)>0.5; open anterior chamber angle; absence of other ocular pathologies; reliable SAP, and good SLP and OCT image quality. Exclusion criteria were: refractive error higher than 4 diopters (D) of sphere and 2.5 D of cylinder; pupils<3 mm in diameter; presence of secondary causes of glaucoma, diabetes mellitus, neurological disorders, previous ocular surgery, or medication that might alter SAP results.

Normal group was consisted of 25 eyes of 25 normal individuals. Inclusion and exclusion criteria were the same as for case group except IOP<22, normal VF on SAP and normal optic nerve head appearance.

GDx VCC imaging (Laser Diagnostic Technology, San Diego, California, USA), and Stratus OCT imaging (Stratus OCT, software 3.0; Carl Zeiss Meditec, Dublin, California, USA) were performed. OCT imaging of the peripapillary RNFL was done using high resolution scans with a diameter of 3.4 mm centered on the optic disc (Fast RNFL scan), and the mean value of three measurements was used. GDx VCC imaging was performed using a scan circle of 3.2 mm diameter centered on the optic disc, and the average of three measurements was used for the second time. All images with quality score grading less than 8 were excluded. Temporal-Superior-Nasal-Inferior-Temporal (TSNIT) average, nerve fiber indicator (NFI), and superior/inferior averages were obtained. Pearson's correlation coefficient (r) was calculated for each pair of parameters, and P-value of less than or equal to 0.005 were considered statistically significant. Area under the receiver operating characteristic curve (AROC) and sensitivity at 90% specificity for each parameter were calculated.

## Results

Eighty-seven glaucomatous eyes of 87 patients were included in this study (41 males). Mean age of patients was 54.96±18.34 (median: 56, range: 35-81). All glaucomatous eyes had VF loss of -5.94±3.18

dB MD (range: -1.95 to -12.11) and  $4.57 \pm 2.87$  PSD.

GDx VCC parameters of peripapillary RNFL were:  $49.96 \pm 15.34$  NFI,  $44.27 \pm 5.31$   $\mu$ m TSNIT average,  $55.71 \pm 10.63$   $\mu$ m superior average, and  $61.45 \pm 8.00$   $\mu$ m inferior average. In Stratus OCT, measured parameters were:  $79.67 \pm 19.22$   $\mu$ m average thickness,  $88.42 \pm 19.27$   $\mu$ m superior average, and  $83.49 \pm 17.90$   $\mu$ m inferior average (Table 1).

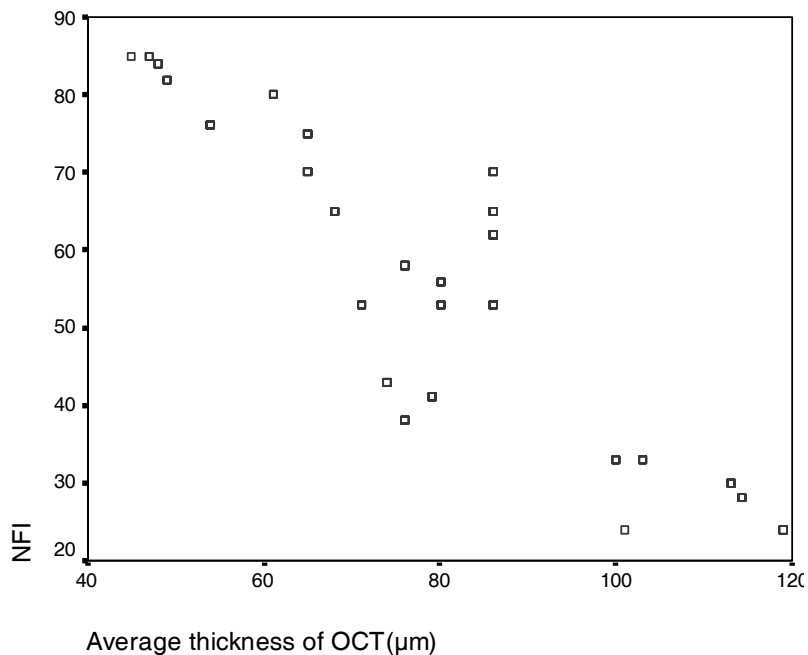
Statistically significant correlations were

observed in each parameter ( $P < 0.005$ ). Pearson coefficients were as follows: -0.858 for NFI/average thickness of OCT (Figure 1), 0.733 for superior average of GDx/superior average of OCT (Figure 2), 0.731 for inferior average of GDx/inferior average of OCT (Figure 3) and 0.748 for TSNIT average of GDx/average thickness of OCT (Figure 4). All correlations were statistically significant in each parameter ( $P < 0.005$ ), and had positive correlations except for the NFI.

**Table 1.** Parameters measurements (Mean $\pm$ SD) of GDx VCC and optical coherence tomography of patients (n=87) and control group (n=25)

	Controls	Patients
NFI	$14.24 \pm 4.50$	$49.96 \pm 15.34$
Average thickness of OCT ( $\mu$ m)	$100.41 \pm 12.39$	$79.67 \pm 19.22$
Superior average thickness of GDx VCC ( $\mu$ m)	$70.65 \pm 6.04$	$55.71 \pm 10.63$
Inferior average thickness of GDx VCC ( $\mu$ m)	$75.36 \pm 6.71$	$61.45 \pm 8.00$
Superior average thickness of OCT ( $\mu$ m)	$120.16 \pm 16.09$	$88.42 \pm 19.27$
Inferior average thickness of OCT ( $\mu$ m)	$121.12 \pm 14.24$	$83.49 \pm 17.90$
TSNIT average ( $\mu$ m)	$60.00 \pm 5.18$	$44.27 \pm 5.31$

OCT: Optical coherence tomography  
 NFI: Nerve fiber indicator  
 TSNIT: Temporal-Superior-Nasal-Inferior-Temporal



**Figure 1.** Scatterplot of average thickness of optical coherence tomography versus nerve fiber indicator

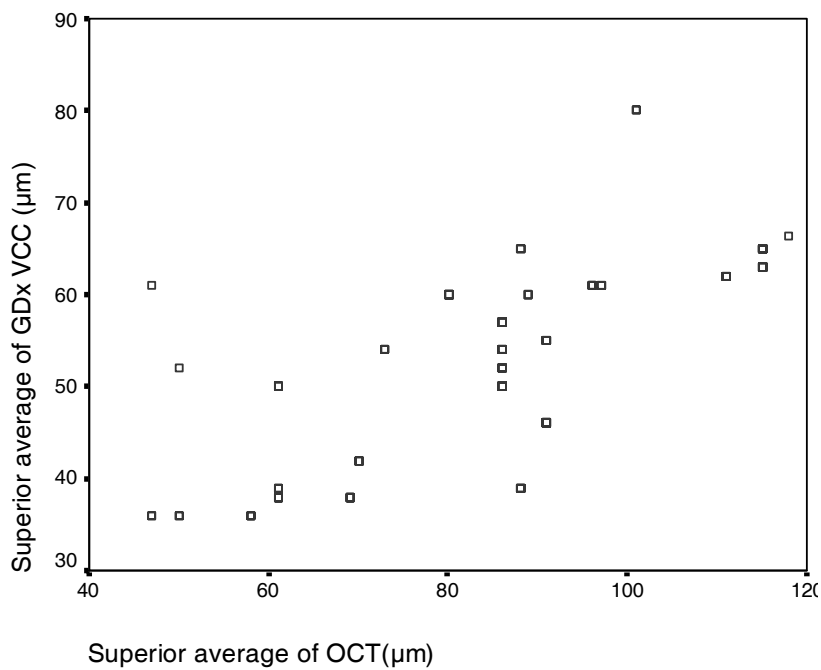


Figure 2. Scatterplot of superior averages

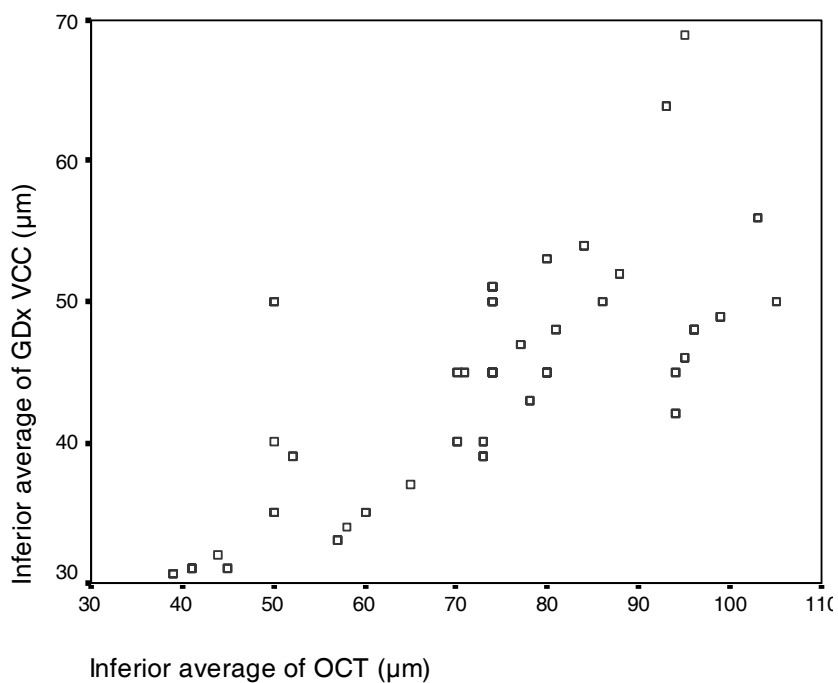
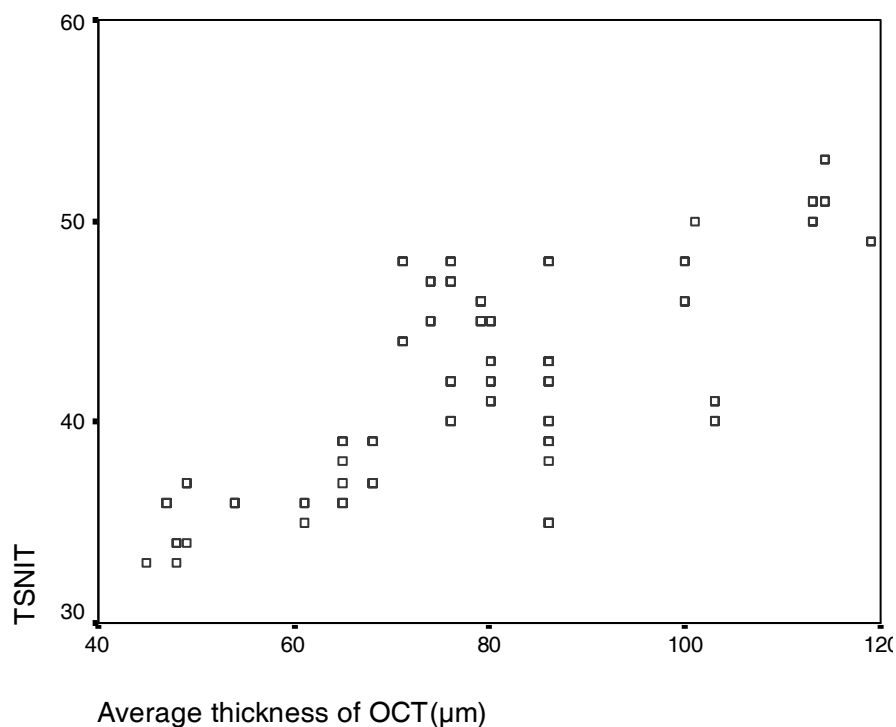


Figure 3. Scatterplot of inferior averages



**Figure 4.** Scatterplot of average thickness of optical coherence tomography versus Temporal-Superior-Nasal-Inferior-Temporal average

The greatest area under AROC parameter in OCT (inferior average 0.78) had a lower area than that in GDx VCC (NFI; 0.95). Area under AROC for GDx parameters ranged from 0.74 to 0.95, with greatest associated with NFI (0.95). The sensitivities at 90% specificity of the GDx parameters ranged from 61% of the superior average to 89% of NFI (Tables 2, 3). For OCT parameters, area under AROC ranged from 0.65 of superior average thickness to 0.78 of inferior average). The sensitivities at 90% specificity of the OCT parameters were greatest for inferior average (73%).

Normal group was consisted of 25 eyes of 25 normal individuals (12 male). Mean age

was  $50.02 \pm 20.15$  (median: 52, range: 30-83). There was no significant difference between two groups in age and gender. MD and PSD in normal group were  $-0.50 \pm 0.56$  and  $1.55 \pm 0.36$ , respectively. GDx parameters in control group were  $14.24 \pm 4.50$  for NFI,  $60.00 \pm 5.18$  for TSNIT average,  $70.65 \pm 6.04$  for superior average and  $75.36 \pm 6.71$  for inferior average. OCT measurements of average thickness, superior average and inferior average were  $100.41 \pm 12.39$ ,  $120.16 \pm 16.09$  and  $121.12 \pm 14.24$ , respectively (Table 1). There was a significant statistical correlation in all VF, GDx VCC, and OCT variables between two groups ( $P$ -value  $< 0.005$ , Pearson correlation test).

**Table 2.** Sensitivity at  $\geq 90\%$  specificity, area under the AROC of GDx VCC indices.

Parameters	Sensitivity at 90% specificity (%)	AROC
NFI	89	0.95
Superior average thickness ( $\mu\text{m}$ )	61	0.74
Inferior average thickness ( $\mu\text{m}$ )	65	0.86
TSNIT	71	0.87

TSNIT: Temporal-Superior-Nasal-Inferior-Temporal  
AROC: Area under the receiver operating characteristic curve  
NFI: Nerve fiber indicator

**Table 3.** Sensitivity at  $\geq 90\%$  specificity, area under the area under the receiver operating characteristic curve of optical coherence tomography indices

Parameters	Sensitivity at 90% specificity (%)	AROC
Average thickness ( $\mu\text{m}$ )	68	0.71
Superior average thickness ( $\mu\text{m}$ )	65	0.69
Inferior average thickness ( $\mu\text{m}$ )	73	0.78

AROC: Area under the receiver operating characteristic curve  
OCT: Optical coherence tomography

## Discussion

In this study, we described the correlation of optic disc retinal thickness indices of GDx VCC and Stratus OCT.

Structural damage of the optic nerve head and peripapillary RNFL precedes detectable VF loss using SAP<sup>11,12</sup>; 40% axonal loss may occur before any detectable findings in SAP.<sup>13,14</sup> However, conventional tools for the structural measurement in glaucoma, such as photography, are subjective and difficult to perform and they are of low scientific Reproducibility.<sup>15,16</sup> So, structural measurement techniques have been recently used to obtain objective quantitative data. GDx and OCT, allow quantitative and reproducible measurements of the ONH and the peripapillary RNFL.<sup>17,18</sup> They can show evidence of RNFL loss up to six years before a detectable change in SAP.<sup>8</sup> Both GDx and OCT are able to provide reproducible measurements of RNFL thickness<sup>17,18</sup> and differentiate glaucomatous eyes from normal.<sup>19,20</sup>

There are some studies concentrated on comparison between GDx VCC and OCT in glaucoma.<sup>2,7-10</sup> The result of our study is in agreement with the previous studies that evaluated correlation of GDx VCC and OCT in glaucoma. Average RNFL thickness measured with Stratus OCT and GDx VCC were highly correlated in Leung et al<sup>10</sup> study. Chung et al also reported that GDx VCC and Stratus OCT are highly correlated in glaucomatous eyes.<sup>7</sup>

In our study, in POAG patients, parameters of GDx VCC and Stratus OCT were significantly correlated with each other. Correlation coefficients were highest for

NFI/average thickness of OCT. TSNIT average/average thickness of OCT, superior average, and inferior average were also well correlated. Higher correlations were also observed in NFI/average thickness of OCT and superior average in previous studies.<sup>7,21</sup>

Between all GDx VCC parameters, it has been described that NFI, which is a global measure of focal and global RNFL loss using neural networks, is the most discriminating one, setting the cut-off point at different levels.<sup>22,23</sup>

The strongest correlation was between NFI and average thickness of OCT, which might be meaningful. The NFI, a major global factor of RNFL loss has high index of discrimination between normal and glaucomatous patients.<sup>10</sup>

It seems that glaucoma firstly damage the inferotemporal and superotemporal areas.<sup>24</sup> Evaluating RNFL thickness in the superior and inferior regions is often the best way of discriminating healthy eyes from eyes with early-to-moderate glaucoma, using OCT. Although some studies have demonstrated that superior average is the best parameter of OCT for detecting glaucomatous eyes,<sup>2,25</sup> in most other studies<sup>5,19,20,26</sup> inferior average had the best diagnostic value. Similar to these studies, in our patients the largest AROC for OCT indices was the inferior average. Brucini<sup>2</sup> demonstrated that the best performing indices for the GDx VCC and OCT gave similar AROCs. In our study NFI of GDx had better discrimination than inferior average of OCT. It had higher sensitivity (89%) than inferior average of OCT at fixed specificity of 90%. Previous studies showed that OCT and GDx had moderate sensitivity with high specificity

for the diagnosis of early glaucoma.<sup>2,27</sup> Most of these studies were concentrated on early stages of glaucoma that had small, localized RNFL defects. One explanation for our better results might be the fact that we did not exclude patients with advanced POAG glaucoma. So the sensitivity of these tests was higher in our study.

There were some limitations in our study. Sample size especially in control group was not too large. Moreover, structural tests in

advanced glaucoma might be variable leading to variable results.<sup>22</sup>

### Conclusion

In conclusion, our results demonstrated that parameters of GDx VCC and Stratus OCT were significantly correlated in primary open angle glaucomatous patients, and we can rely on both two techniques to document objective measurements in this group of patients.

### References

1. Ma KT, Lee SH, Hong S, et al. Relationship between the retinal thickness analyzer and the GDx VCC scanning laser polarimeter, Stratus OCT optical coherence tomograph, and Heidelberg retina tomograph II confocal scanning laser ophthalmoscopy. *Korean J Ophthalmol* 2008;22(1):10-7.
2. Brusini P, Salvatet ML, Zeppieri M, et al. Comparison between GDx VCC scanning laser polarimetry and Stratus OCT optical coherence tomography in the diagnosis of chronic glaucoma. *Acta Ophthalmol Scand* 2006;84(5):650-5.
3. Izatt JA, Hee MR, Swanson EA, et al. Micrometer-scale resolution imaging of the anterior eye in vivo with optical coherence tomography. *Arch Ophthalmol* 1994;112(12):1584-9.
4. Huang XR, Knighton RW. Linear birefringence of the retinal nerve fiber layer measured in vitro with a multispectral imaging micropolarimeter. *J Biomed Opt* 2002;7(2):199-204.
5. Medeiros FA, Zangwill LM, Bowed C, et al. Fourier analysis of scanning laser polarimetry measurements with variable corneal compensation in glaucoma. *Invest Ophthalmol Vis Sci* 2003;44(6):2606-12.
6. Medeiros FA, Zangwill LM, Bowed C, et al. Evaluation of retinal nerve fiber layer, optic nerve head, and macular thickness measurements for glaucoma detection using optical coherence tomography. *Am J Ophthalmol* 2005;139(1):44-55.
7. Chung YS, Sohn YH. The relationship between optical coherence tomography and scanning laser polarimetry measurements in glaucoma. *Korean J Ophthalmol* 2006;20(4):225-9.
8. Greaney MJ, Hoffman DC, Garway-Heath DF, et al. Comparison of optic nerve imaging methods to distinguish normal eyes from those with glaucoma. *Invest Ophthalmol Vis Sci* 2002;43(1):140-5.
9. Bagga H, Greenfield DS, Feuer W, Knighton RW. Scanning laser polarimetry with variable corneal compensation and optical coherence tomography in normal and glaucomatous eyes. *Am J Ophthalmol* 2003;135(4):521-9.
10. Leung CK, Chan WM, Chong KK, et al. Comparative study of retinal nerve fiber layer measurement by Stratus OCT and GDx VCC, I: correlation analysis in glaucoma. *Invest Ophthalmol Vis Sci* 2005;46(9):3214-20.
11. Sheffield VC, Stone EM, Alward WL, et al. Genetic linkage of familial open angle glaucoma to chromosome 1q21-q31. *Nat Genet* 1993;4(1):47-50.
12. Sommer A, Katz J, Quigley HA, et al. Clinically detectable nerve fiber atrophy precedes the onset of glaucomatous field loss. *Arch Ophthalmol* 1991;109(1):77-83.
13. Quigley HA, Addicks EM, Green WR. Optic nerve damage in human glaucoma. III. Quantitative correlation of nerve fiber loss and visual field defect in glaucoma, ischemic neuropathy, papilledema, and toxic neuropathy. *Arch Ophthalmol* 1982;100(1):135-46.
14. Quigley HA, Dunkelberger GR, Green WR. Retinal ganglion cell atrophy correlated with automated perimetry in human eyes with glaucoma. *Am J Ophthalmol* 1989;107(5):453-64.
15. Quigley HA. Examination of the retinal nerve fiber layer in the recognition of early glaucoma damage. *Trans Am Ophthalmol Soc* 1986;84:920-66.

16. Honrubia F, Calonge B. Evaluation of the nerve fiber layer and peripapillary atrophy in ocular hypertension. *Int Ophthalmol* 1989;13(1-2):57-62.
17. Weinreb RN, Shakiba S, Zangwill L. Scanning laser polarimetry to measure the nerve fiber layer of normal and glaucomatous eyes. *Am J Ophthalmol* 1995;119(5):627-36.
18. Schuman JS, Pedut-Kloizman T, Hertzmark E, et al. Reproducibility of nerve fiber layer thickness measurements using optical coherence tomography. *Ophthalmology* 1996;103(11):1889-98.
19. Bowd C, Zangwill LM, Berry CC, et al. Detecting early glaucoma by assessment of retinal nerve fiber layer thickness and visual function. *Invest Ophthalmol Vis Sci* 2001;42(9):1993-2003.
20. Zangwill LM, Bowd C, Berry CC, et al. Discriminating between normal and glaucomatous eyes using the Heidelberg retina tomograph, GDx nerve fiber analyzer, and optical coherence tomograph. *Arch Ophthalmol* 2001;119(7):985-93.
21. Kanamori A, Nakamura M, Escano MF, et al. Evaluation of the glaucomatous damage on retinal nerve fiber layer thickness measured by optical coherence tomography. *Am J Ophthalmol* 2003;135(4):513-20.
22. Reus NJ, Lemij HG. Diagnostic accuracy of the GDx VCC for glaucoma. *Ophthalmology* 2004;111(10):1860-5.
23. Colen TP, Tang NE, Mulder PG, Lemij HG. Sensitivity and specificity of new GDx parameters. *J Glaucoma* 2004;13(1):28-33.
24. Mabuchi F, Aihara M, Mackey MR, et al. Regional optic nerve damage in experimental mouse glaucoma. *Invest Ophthalmol Vis Sci* 2004;45(12):4352-8.
25. Nouri-Mahdavi K, Hoffman D, Tannenbaum DP, et al. Identifying early glaucoma with optical coherence tomography. *Am J Ophthalmol* 2004;137(2):228-35.
26. Zareii R, Soleimani M, Moghimi S, et al. Relationship between GDx VCC and Stratus OCT in juvenile glaucoma. *Eye* 2009 Feb 20. [Epub ahead of print]
27. Parikh RS, Parikh S, Sekhar GC, et al. Diagnostic capability of optical coherence tomography (Stratus OCT 3) in early glaucoma. *Ophthalmology* 2007;114(12):2238-43.